

THE ANATOMIC AND PHYSIOLOGIC BASIS OF LOCAL, REFERRED AND RADIATING LUMBOSACRAL PAIN SYNDROMES RELATED TO DISEASE OF THE SPINE

J. RANDY JINKINS

Department of Radiology, Downstate Medical Center, State University of New York, 450 Clarkson Avenue, Brooklyn, NY 11203, USA.

SUMMARY

Conscious perception and unconscious effects originating from the vertebral column and its neural structures, although complex, have definite pathways represented in a network of peripheral and central nervous system (CNS) ramifications. These neural relationships consequently result in superimposed focal and diffuse, local and remote conscious perceptions and unconscious effects. Any one or combination of somatic and autonomic signs and symptoms may potentially be observed in a particular patient. This variety and inconsistency may mislead or confuse both the patient and the physician. A clear understanding of the basic anatomic and physiologic concepts underlying this complexity should accompany clinical considerations of the potential significance of spondylogenic and neurogenic syndromes in any disease process affecting the spine.

Key words: anatomy, pain, physiology, spine.

RÉSUMÉ

Bases anatomiques et physiologiques des syndromes douloureux d'origine rachidienne

La perception consciente et les effets inconscients provenant du rachis et des structures spinales empruntent un réseau complexe appartenant aux systèmes nerveux central et périphérique. Ces rapports nerveux ont pour conséquence des effets inconscients et des sensations focaux et diffus, locaux et à distance. Signes et symptômes végétatifs et somatiques peuvent être observés chez un patient donné de façon isolée ou combinée. Cette expression variable et incohérente des signes peut tromper patient et clinicien. La compréhension des données anatomiques et physiologiques qui sous tendent cette complexité, est nécessaire pour comprendre les syndromes vertébraux et nerveux observés en cas de lésion rachidienne

Mots-clés : anatomie, physiologie, douleur, rachis.

INTRODUCTION

The clinical state accompanying nonspecific injury to the spinal column and perispinal soft tissues may be manifest in a complex combination of somatic and autonomic syndromes. The overall combined symptom complex includes: local somatic spinal pain, radiating radicular pain, radiating/radicular paresthesias, radiating/referred skeletal muscle spasm/dysfunction, radiating/referred autonomic dysfunction, referred pain, and referred generalized alterations in viscerosomatic tone. In practice these clinical manifestations are typically superimposed upon one another and are of varying individual expression.

The anatomic basis for the origin and mediation of clinical signs and symptoms originating within the lumbosacral spine is related to direct spinal innervation, the spinal nerve roots and nerves, and the lumbosacral sympathetic plexus. Specifically, the relevant neural structures include: afferent and efferent somatic neural branches emanating from the ventral and dorsal rami of the lumbosacral spinal nerves, neural

branches projecting to and originating from the paravertebral autonomic (sympathetic) neural plexus and the spinal nerves/lumbosacral plexi themselves. Neural fibers from these structures originate and terminate in the spinal column and related nonneural tissues (e.g., bone, periosteum, meninges, spinal ligaments, perispinal musculature, spinal column and perispinal blood vessels) in the spinal neural tissue itself (e.g., spinal rami, nerves), and in the distant peripheral tissues within the somatic and visceral distribution of these nerves (e.g., spinal column, perispinal soft tissues, buttocks, lower extremities, pelvis). Finally, the intimate connections of these neural structures with the central nervous system, including the spinal cord and the higher cortical and noncortical centers of the cerebrum, are ultimately responsible for the manifestations of clinical syndromes in the patient with relevant spinal disease [10, 18, 35].

Thus, conscious perception and unconscious effects originating from the vertebral column, its neural structures and the surrounding tissues, although complex, have definite pathways represented in this network of peripheral and central nervous system (CNS) ramifications. Although the

model for this discussion will center on the lumbosacral spine, the particulars apply to all levels of the spine, after allowing for regional modifications.

ANATOMY OF LOCAL SPINAL SYNDROMES

Somatic Innervation of Ventral Spinal Elements

Innervation of the ventral spinal tissues rests partially with afferent *somatic* fibers originating from the recurrent meningeal nerve (sinuvertebral nerve of von Luschka) supplying the posterior longitudinal ligament, the meninges of the anterior aspect of the thecal sac, the regional anterior epidural blood vessels (arteries and veins), the posterior aspect of the outermost fibers of the annulus fibrosis, the anterior and posterior longitudinal ligaments and the posterior portion of the periosteum of the vertebral body and related tissues over an inconstant range. In addition, irregular, unnamed afferent branches directly emanating from the ventral rami of the somatic spinal nerves themselves also contribute to direct spinal and adjacent perispinal soft tissue innervation laterally. Thus, these well-defined somatic neural networks form the anatomic basis for *discogenic* (intervertebral disc), *spondylogenic* (spinal bony structures), *musculogenic* (intrinsic spinal and external perispinal muscles), *ligamentogenic* (intrinsic spinal ligaments) normal sensation and pathologic pain [23, 36, 45, 48, 74, 90, 91].

Any insult of these neural and non-neural tissues may incite well-circumscribed local somatic pain because of this characteristic somatosensory innervation pattern (*figure 1*), and because of the direct segmental nature of the afferent inflow from the segment of origin into the CNS via the somatic spinal nerves (*figure 2a*) [6, 9, 20, 23, 29, 38, 52, 63, 87, 90, 91]. This direct somatosensory afferent inflow seems

to embryologically insure a relatively accurate CNS somatotopic spatial registration of impulses incoming into the CNS with regard to stimulus origin, and thus *local* spine pain.

Somatic Innervation of Dorsal Spinal Elements

The dorsal rami of the spinal nerves give rise to medial and lateral main branches. These neural structures innervate the posterior spinal facet (zygapophyseal) joints (bone, periosteum, articular structures including the joint capsule), the lateral and posterior vertebral bony elements (laminae, transverse and spinous processes), as well as the surrounding posterior (dorsal) intrinsic spinal and perispinal muscular (multifidus, interspinalis muscles), and ligamentous tissues (interspinous ligament, supraspinous ligament).

In total there are potentially five or more main branches innervating these structures that are of somewhat irregular origin. These branches include neural fibers arising directly from the main trunk of the dorsal ramus of the spinal nerve, from the medial branch of the dorsal ramus, from the lateral branch of the dorsal ramus, and from the combined spinal nerve itself before its bifurcation into the dorsal and ventral rami (*figure 3*) [2, 5, 8].

On careful anatomic study, the dorsal elements of the spinal column and surrounding tissues have been demonstrated to have remarkably variable fields of innervation that are not confined to strict segmental patterns. This innervation shows bilateral asymmetry with intra- and interindividual variation in the cranio-caudal extent of the neural supply.

Nevertheless, injury to these neural and non-neural spinal/perispinal tissues would in part, be expected to result in well localized somatic pain because of the direct afferent somatosensory inflow into the CNS via the retrospective somatic spinal nerves. Thus, in general this neural handling of pain seems to occur in a manner similar to that outlined

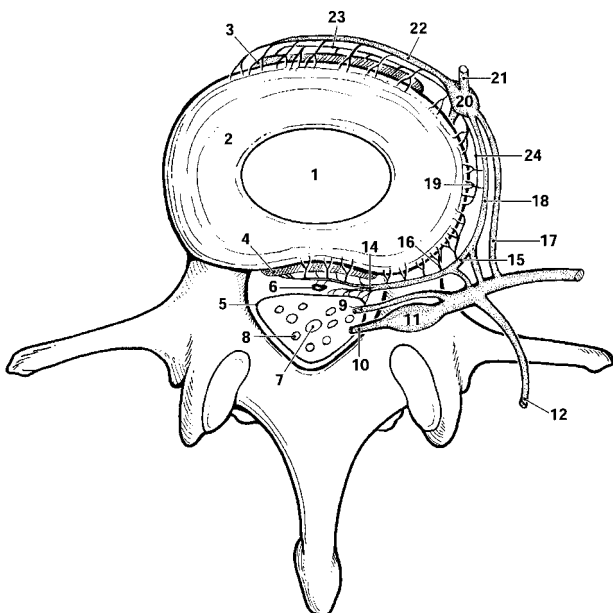


FIG. 1.— Schematic illustrating somatic and autonomic innervation of ventral (anterior) spinal canal and structures of ventral aspect of spinal column. (1=nucleus pulposus; 2=annulus fibrosus; 3=anterior longitudinal ligament/periosteum; 4=posterior longitudinal ligament/periosteum; 5=thecal sac; 6=tissues within anterior epidural space [e.g., epidural vasculature]; 7=filum terminale; 8=intrathecal nerve root [s] of the cauda equina; 9=ventral nerve root; 10=dorsal nerve root; 11=dorsal root ganglion; 12=dorsal ramus of spinal nerve; 13=ventral ramus of spinal nerve; 14=recurrent meningeal nerve [sinuvertebral nerve of Luschka]; 15=connecting sympathetic branch from gray ramus communicans to the sinuvertebral nerve of Luschka [sympathetic branch to recurrent meningeal nerve]; 16=neural radicals from sinuvertebral nerve of Luschka to posterior and lateral aspect of intervertebral disc surface; 17=white ramus communicans [not found or found irregularly caudal to L2]; 18=gray ramus communicans; 19=sympathetic neural radicals to lateral disc surface from gray ramus communicans; 20=paraspinal sympathetic ganglion [PSG]; 21=paraspinal sympathetic chain on left side [replicated on right side: not shown]; 22=anterior branch from sympathetic ganglion to anterior disc surface; 23=branches from sympathetic chain to anterior disc surface.] [Note: afferent and efferent sympathetic paraspinal branches/rami may be partially combined *in vivo*.]

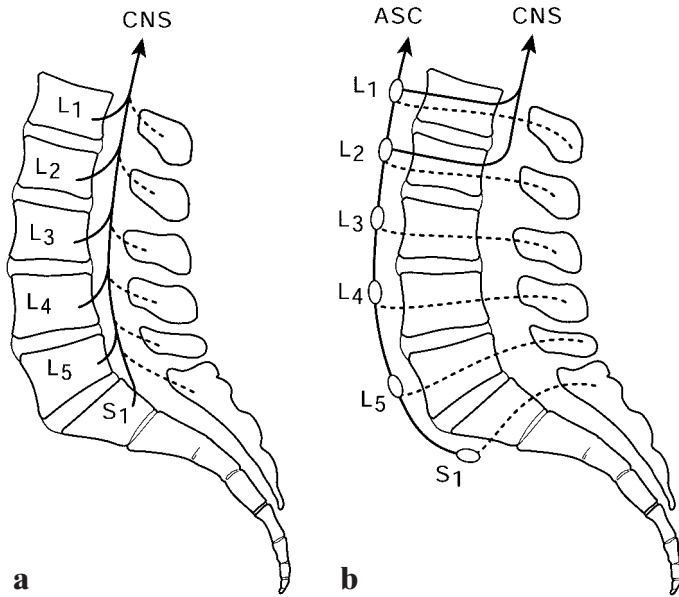


FIG. 2. – Schematics illustrating lumbar afferent sensory patterns. a) Direct somatic afferent inflow into central nervous system (CNS) from branches of somatic spinal nerves at all levels. b) Ascending autonomic (sympathetic) afferent inflow diversion into CNS of lumbosacral sympathetic fibers. This inflow pattern is inconstant due to the absence or irregular distribution of white rami communicantes occurring between the L2 and S2 vertebral levels. (ASC=ascending sympathetic chain; large diameter solid lines=afferent sympathetic network; short arrows=afferent sympathetic inflow from ventral spinal elements; dashed lines=afferent sympathetic inflow from dorsal spinal elements).

above for the ventral spinal elements (figure 2a). In other words, these neural structures contribute to direct posterior (dorsal) spinal and perispinal soft tissue innervation, and thus somatic *spondylogenic*, (posterior bony spinal tissues), *articulogenic* (posterior spinal facet joints), *ligamentogenic* (ligamenta flava, interspinous ligament, supraspinous ligament) and *musculogenic* (multifidus, interspinalis muscles) normal sensation and *local spinal pain* [1, 10, 36, 45, 48, 74, 91].

Additional Considerations in the Innervation of Spinal Elements

Local innervations at the level of the dorsal and ventral roots, spinal nerves, recurrent meningeal nerves and other epidural structures at the point of common expression of pathology (e.g., interver-

tebral disc herniation, spinal stenosis) is an important consideration regarding the understanding of the manifestations of the lumbosacral syndromes. In addition to peripheral and local somatic afferent sensory and efferent motor nerves traversing this region (figure 4a-c), there are nerve fibers innervating the nerves themselves, the *nervi nervorum* [21].

These *nervi nervorum* are theoretically of three types. First, there are afferent somatic sensory fibers to the main nerve radicles in, traversing and around the spinal column (figure 4d). These are responsible for local sensation and even pain when the nerve itself is perturbed or nonspecifically injured. Second, there are local tissue and intrinsic radicular sympathetic afferent fibers. Upon leaving the spine, these fibers enter the paraspinal sympathetic chain via the gray rami communicantes and return to the CNS via the white rami

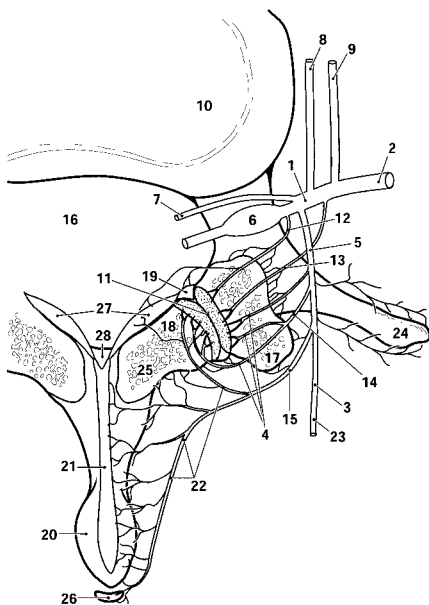


FIG. 3. – Schematic illustrating innervation of structures of dorsal (posterior) aspect of spinal column. (1=main trunk of spinal nerve; 2=ventral ramus of spinal nerve; 3=lateral branch of dorsal ramus of spinal nerve; 4=neural fibers to posterior dorsal ramus of spinal nerve; 5=dorsal ramus of spinal nerve; 6=dorsal nerve root and ganglion; 7=ventral nerve root; 8=gray ramus communicans; 9=white ramus communicans; 10=intervertebral disc; 11=articular cartilage of posterior spinal facet [zygapophyseal] joint; 12=neural fibers from main trunk of spinal nerve; 13=neural fibers to posterior facet joint from ventral ramus of spinal nerve; 14=neural fibers to posterior facet joint from dorsal ramus; 15=medial branch of dorsal ramus; 16=central spinal canal; 17=superior articular facet process; 18=inferior articular facet process; 19=zygapophyseal joint space and capsule; 20=spinous process; 21=interspinous ligament; 22=medial neural branches ramifying within posterior spinal facet joint, the lamina, spinous process, interspinous ligament, and supraspinous ligament; 23=branch of dorsal ramus ramifying within posterior perispinal tissues; 24=transverse process; 25=lamina; 26=supraspinous ligament; 27=ligamenta flavum; 28=median retrothecal fat pad).

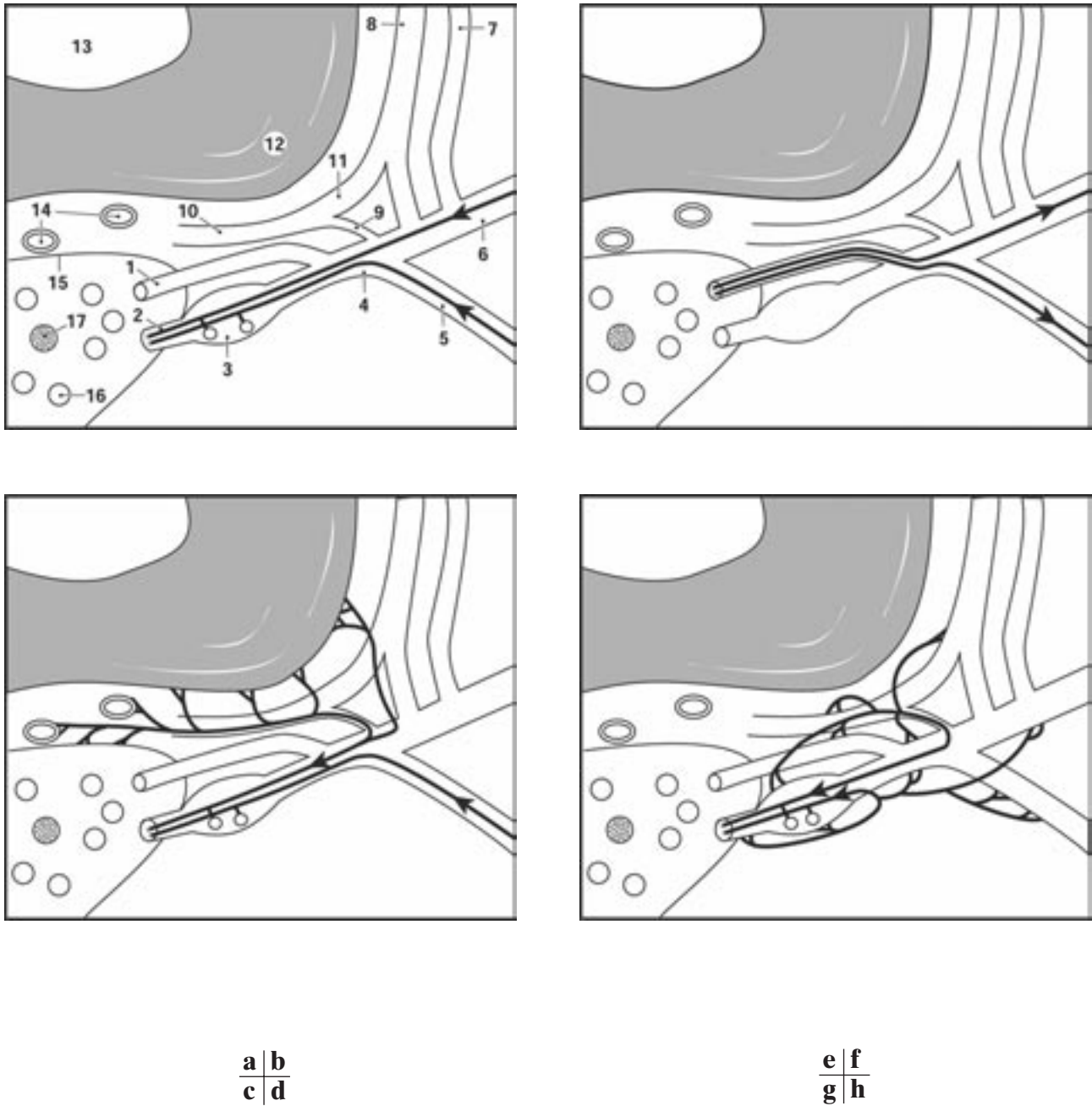
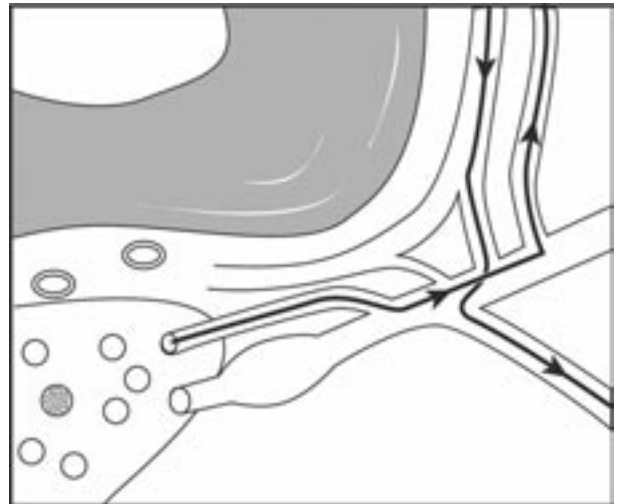
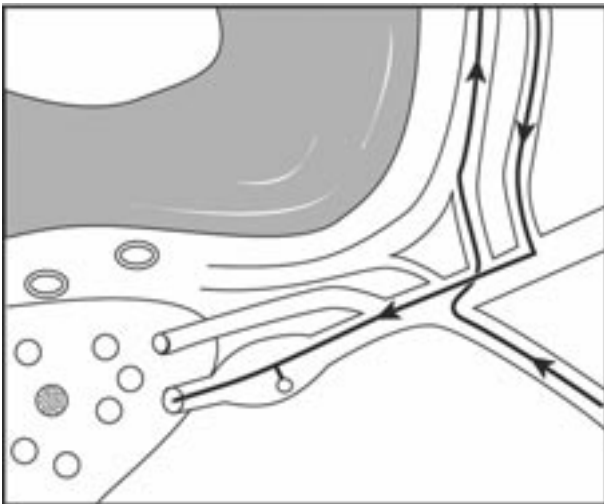
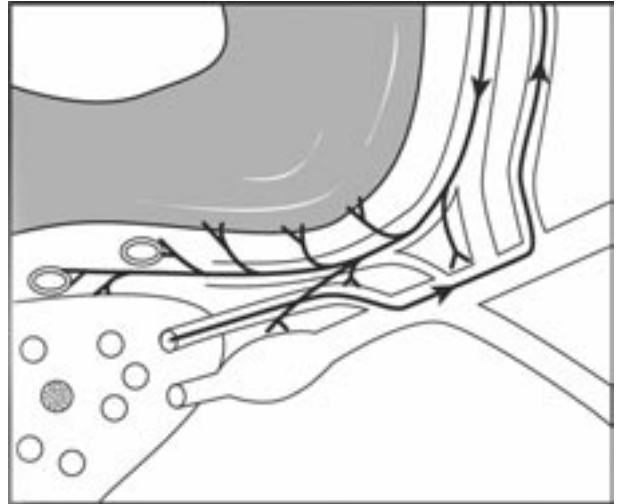
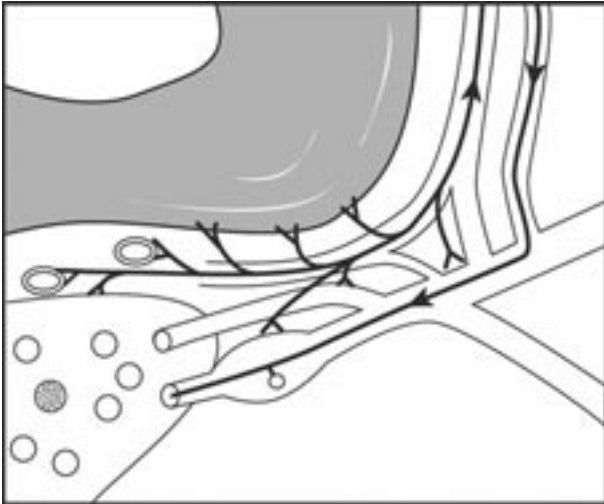


FIG. 4. – Schematics of somatic and autonomic (sympathetic) innervation of spinal column and related structures. a) Peripheral somatic afferent sensory neural fibers from ventral and dorsal tissues carried within the dorsal and ventral rami joining the spinal nerve proper. b) Peripheral somatic efferent motor neural fibers to ventral and dorsal tissues carried within the dorsal and ventral rami joining the spinal nerve proper. c) Local somatic afferent sensory neural fibers (including those within the recurrent meningeal nerve) from ventral, intra- and perispinal tissues (e.g., peripheral disc, epidural tissues, dura, etc.), and dorsal spinal, perispinal tissues (e.g., facet joints, posterior spinal ligaments, posteromedial perispinal musculature, etc.). d) Local/radicular afferent *nervi nervorum*. e) Local/radicular sympathetic afferent neural fibers (including those within the recurrent meningeal nerve) from ventral spinal, intra- and perispinal tissues (e.g., peripheral disc, epidural tissues, dura, etc.). f) Local/radicular sympathetic efferent neural fibers (including those within the recurrent meningeal nerve) to ventral spinal, intra- and perispinal tissues (e.g., peripheral disc, epidural tissues, dura, etc.). g) Local sympathetic afferent neural fibers from dorsal spinal and perispinal tissues (e.g., facet joints, posterior spinal ligaments, posteromedial perispinal musculature, etc.). h) Local sympathetic efferent neural fibers to dorsal spinal and perispinal tissues (e.g., facet joints, posterior spinal ligaments, posteromedial perispinal musculature, etc.). (1=ventral nerve root; 2=dorsal nerve root; 3=dorsal root ganglion; 4=combined spinal nerve; 5=dorsal ramus of spinal nerve; 6=ventral ramus of spinal nerve; 7=white ramus communicans [not found or irregularly found caudal to L-1,2]; 8=gray ramus communicans; 9=branch to recurrent meningeal nerve from spinal nerve; 10=recurrent meningeal nerve [sinuvertebral nerve of Luschka]; 11=autonomic [sympathetic] branch to recurrent meningeal nerve from gray ramus communicans; 12=annulus fibrosus; 13=nucleus pulposus; 14=epidural vasculature; 15=leptomeninges; 16=intrathecal lumbosacral nerve root; 17=filum terminale).



communicantes (*figure 4e*). These fibers relay afferent information from the spinal roots, nerves and surrounding tissues to the somatic and sympathetic nervous systems. Third, there are local/radicular sympathetic efferent fibers which carry out sympathetic actions (e.g., vasoactive functions) upon the spinal roots, nerves and surrounding tissues (*figure 4f*).

This general format of spinal innervation is likely replicated in its essential points in the spinal and perispinal tissues, the autonomic fibers being initially transmitted via the dorsal roots of the spinal nerves, and later traveling in company with the blood vessels supplying these tissues (*figure 4g-h*) [2, 7, 16].

With this level of neuroanatomic complexity, it is not surprising that pathology affecting this particular region would be expected to potentially be somewhat confusing in its clinical manifestations. All possible somatoautonomic expressions (e.g., local pain, referred pain, radicular pain, autonomic dysfunction [see below]) could possibly emanate from this network of afferent and efferent fibers that traverse this area as well as originate and terminate here. At the same time, injury to somatic efferent motor fibers contained in the ventral/dorsal rami of the spinal nerve or the spinal nerve itself might yield muscular weakness, spasm and muscle reflex dysfunction. This

surely must be one of the more neurologically labyrinthine regions in the entire peripheral nervous system. Why each patient might be expected to have a unique and compound-complex array of signs and symptoms can be easily appreciated if these intimately related anatomic neural ramifications are taken into account.

ANATOMY OF CENTRIPETALLY/ CENTRIFUGALLY REFERRED SPINAL SYNDROMES

As noted above, many afferent fibers from the spinal column project immediately to the paraspinal sympathetic ganglia [29]. Afferent polymodal pain fibers traversing the sympathetic ganglia have been identified in all of the vertebral structures except the central areas of the annulus fibrosus and the nucleus pulposus. The tissues innervated by sympathetic fibers include the longitudinal ligaments, the most peripheral laminae of the annulus fibrosus, the periosteum of the vertebral body, the vertebral body itself, the posterior bony elements (posterior spinal facet joints, laminae, spinous processes) and the spinal and perispinal soft tissues (blood vessels, muscles, ligaments) [16, 20, 36, 38, 63, 77, 78].

A major autonomic branch also extends on both sides posteriorly from either the sympathetic ganglion directly or indirectly from the gray ramus communicans to make up the bulk of the recurrent meningeal nerve (*figure 4e*) [6, 42, 46]. Thus, afferent sympathetic fibers supply the whole of the disc periphery, and indeed the entire vertebral column [1]. This extensive network, known as the *paravertebral autonomic neural plexus*, was initially detailed by Stilwell in 1956 (*figure 1*) [77].

Depending on the vertebral level, after traversing the sympathetic ganglia many of these primary afferent fibers subsequently enter the ventral ramus of the somatic spinal nerve via the white ramus communicans [80]. These axons then pass into the dorsal root ganglion, where their cell bodies lie (*figure 4e*). Afterward, the dorsal nerve root carries the fibers until they penetrate the dorsolateral aspect of the spinal cord within the tract of Lissauer, adjacent to the dorsal-horn gray matter.

The anatomic path and embryologic origin of these neural elements within the *autonomic* nervous system contribute in part to the imperfect conscious perception and somatic localization of many pain stimuli [19]. Conscious *somatotopic* localization of pain is normally registered embryologically largely by means of the point of spatial entry of afferent fibers, and therefore neural impulses, into the CNS. Another way of saying this is the means by which the cerebrum understands (i.e., imagines) the point of a painful stimulus in the adult organism is dependent upon the somite of impulse origin must be isolevel with the somite of the spinal nerve serving that particular somite in order to obtain accurate somatotopic localization of the impulse origin within the CNS. For example, a somatic axon impulse entering the CNS (i.e., spinal cord) at the L5 level will be perceived mentally at higher CNS centers in the L5 somatotopic sensory region.

Some pain related impulses entering afferent sympathetic fibers may result in appropriately localized symptomatology such as pain [19], while other axons will be involved with important or even inappropriate autonomic reflex functions [4]. Impulses within yet different (or perhaps the same) afferent fiber, however, will result in the conscious mental picture of remote pain (i.e., perceived in the groin, pelvis, gluteal area, proximal posterolateral thigh). Such *referred pain* is mentally projected to the region corresponding generally to the somatic distribution of the afferent fibers of the spinal nerve with which the afferent sympathetic fibers entered the spinal canal en route to the CNS, as was noted above for the somatic nervous system.

A *somatome* is in part defined as a field of somatic and autonomic innervation that is based on the embryologic segmental origin of the somatic tissues [37]. The complete somatome is composed of three basic elements: the cutaneous structures (*dermatome*), the skeletal musculature (*myotome*), and the bones, joints, and ligaments (*sclerotome*). The term "somatic" indicates that these tissues originate embryonically from the precursor somites [64]. Tissues originating from the same somite, therefore, will have a common neural

circuitry and thus a common pathway of neural referral. Thus, distant pain referral is mentally "projected" to these distant fields of innervation, within the lumbosacral somatomes. The conscious somatic registration (or perhaps mental illusion) of referred pain is perceived peripherally by the brain within what have come to be known as the *lumbosacral zones of Head*, named after Henry Head who originally described these areas in 1893 [31]. Unfortunately these peripheral regions of pain referral are found in the same physical distribution as is the radiating pain seen in true neurogenic sciatica. It is for this reason that referred pain is sometimes termed "pseudoradicular" pain. Nevertheless, these zones of Head (as compared to the cutaneous dermatomes) are irregular, constricted, bilaterally asymmetric, and partially superimposed upon one another [24, 43, 45, 47, 53, 54]. Moreover, they are somewhat inconsistent from person to person (*figure 5*) [55]. Proof that the referred pain's origin is a process intimately involving an afferent limb of the peripheral nervous system, and that the illusory mental perception of distant referred pain is a mechanism of the CNS, is confirmed by the experimental finding that local anesthesia of the actual region of impulse origin (i.e., spinal tissues) abolishes the pain referral, however, anesthesia of the site of referral (i.e., the zone of Head) does not consistently ablate this referred pain [17, 28].

The referred nature and poor definition of the pain are potentially further complicated by the distribution patterns of the sympathetic afferent fibers of the spine, which overlap craniocaudally as well as across the midline. In other words, there is neither true anatomic midline nor accurate segmental

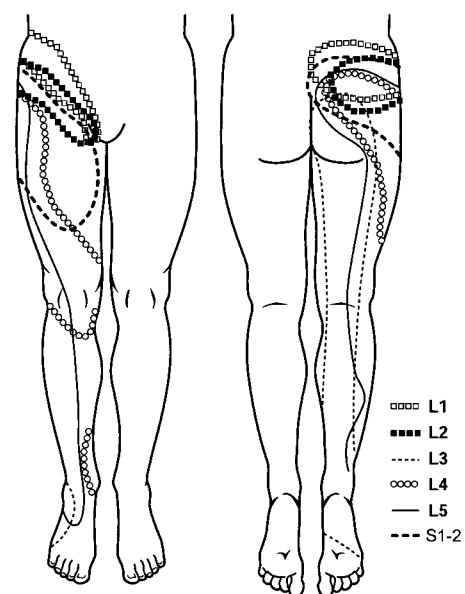


FIG. 5.—Schematics of right unilateral composite of lumbosacral zones of Head representing regions of pain referral and proposed reflex autonomic dysfunction referral from segmental spinal levels (L1-S1, 2). Note the constricted, superimposed, and skipped regions. a) Anterior aspect. b) Posterior aspect.

nature of the lumbosacral paravertebral autonomic (sympathetic) nervous system. In addition, after afferent sympathetic fibers enter the paraspinal sympathetic ganglia, they cannot always exit directly into the nearby somatic ventral or dorsal rami of the spinal root. These fibers instead may have to ascend to a more cranial level before entering the spine. The reason for this is because the afferent fibers can only join the spinal nerves and subsequently enter the CNS via the *white rami communicantes*. An important anatomic pattern and peculiarity of the lumbosacral spine illustrates that there are no, few or irregularly distributed white rami communicantes below the L2 vertebral level and above the S2 level [27]. Any sympathetic afferent fibers from the lower lumbar and upper sacral region (i.e., between the L2 to S2 levels) therefore must ascend within the paravertebral sympathetic chain before they are able to enter the spine at a level that has a white ramus communicans (*figure 2*). As a result of this *autonomic inflow diversion* [26, 56, 58, 59, 78-82], sympathetic pain impulses emanating from lumbosacral regions that do not have white rami communicantes (L3 to S1 levels) will be referred to the somatome corresponding to the final spinal entry level of the afferent fiber (L2 or above). Thus, the conscious perception of sympathetically mediated pain will be misregistered in the CNS (sensory cortex of cerebrum), and pain *referral* will thereby occur to a somatome different from that which its origin would have indicated. This may also possibly result in summing of pain sensation due to the superimposition of afferent fiber input from several different levels [28]. These observations might explain the partial segmental superimposition and irregular contracted nature of the zones of Head in the lumbosacral region, as depicted in *figure 5* [24]. It should also be noted that the overlapping areas of most common centrifugal pain referral from all lumbar levels in fact fall largely within the area of the cutaneous dermatomes of the upper lumbar spinal nerves (i.e., along the inflow pathway of the ascending sympathetic afferent diversion into the L2 spinal nerves and perhaps above).

These unusual lumbosacral innervation patterns may also engender local referred pain to the spine itself and its surrounding tissues [29]. Conscious pain referral originating in the spinal column and spinal neural tissue and subsequently projected to the lumbosacral zones of Head is linked with spinal nerves that coincidentally have afferent somatic projection fields within spinal and perispinal structures. In other words, an integral component of the somatomes of spinal nerves (e.g., myotomes, sclerotomes) includes the spinal elements themselves. Thus, although the local referred pain is not perceived at the precise point of origin in the spine, it is still consciously imagined diffusely in the region of the low back [24, 37, 47, 54].

A combination of local referred, distant referred and local somatic pain when combined with the sometimes concurrent radiating radicular neurogenic pain (see next section), seems to partly explain the parallel systems operating in the spinal column

responsible for the complex and often superimposed syndromes of spinal pain [16, 28].

Further inspection of *figure 5* reveals the sparse areas of nonsuperimposed pain referral extending distally into the lower extremities. This pattern may be explained by the fact that there is direct sympathetic afferent inflow into the S2-S4 pelvic somatic nerve roots, and also by the observation that the sympathetic innervation of spinal structures may originate from as few as three and as many as five different adjacent spinal levels [90]. Hence, direct, multisegmental sacral nerve inflow, and therefore direct pain referral may occur over relatively wide areas [24, 71, 90]. These general anatomic concepts help to clarify some of the mechanisms within the peripheral nervous system responsible for the rather nebulous fields that are characteristic of the zones of Head.

As the foregoing indicates, the majority if not the entire peripheral network resulting in the perception of referred pain could potentially be mediated within the sympathetic nervous system. The peripheral neurologic system follows two patterns during embryologic development: somatic and autonomic. The somatic nervous system has one distribution, which ramifies solely within the somatic tissues. However, the autonomic (sympathetic) nervous system develops along two distinct different pathways: 1) one within visceral tissues sometimes referred to as the *visceral tissue autonomic nervous system*, and 2) one within the somatic tissues in a distribution similar to that of the peripheral somatic nerves that might be called the *somatic tissue autonomic nervous system* (carrying afferent and efferent sympathetic fibers from and to the somatic tissues). Logically there must be such parallel sympathetic afferent links to the CNS in order to complete somatic tissue autonomic reflex arcs (*figure 6a*). Normal autonomic functions depend upon this (e.g., vasomotor, sudomotor and piloerector functions). In fact, the presence of these peripheral autonomic fibers within somatic tissues have been clearly demonstrated [1, 19, 36, 71, 78, 80]. Because both visceral and somatic tissues are innervated by the sympathetic nervous system, and assuming that both tissues are served by afferent limbs, the CNS may then perceive an impulse origin within either tissue (visceral, somatic) or both on the basis of a central embryologically predetermined linkage. In actuality, however, the CNS (sensory cortex) may not be able to accurately discriminate spatially between the visceral and the somatic origin of a stimulus in certain circumstances. Thus, a visceral sympathetic afferent stimulus may erroneously be consciously perceived as arising within the somatic sector of the sympathetic afferent sensory projection field, and by definition is thus *referred* mentally to this location. The converse of this phenomenon might also be true, although perhaps more rarely perceived [4].

As an example, this explanation concisely fits the observation of referral of visceral sympathetic stimuli (e.g., cardiac injury and related pain) to the somatic sympathetic afferent projection field (e.g., left shoulder), thereby defining the zones of Head predominantly or entirely as a phenomenon of a developmentally dichotomous sympathetic nervous

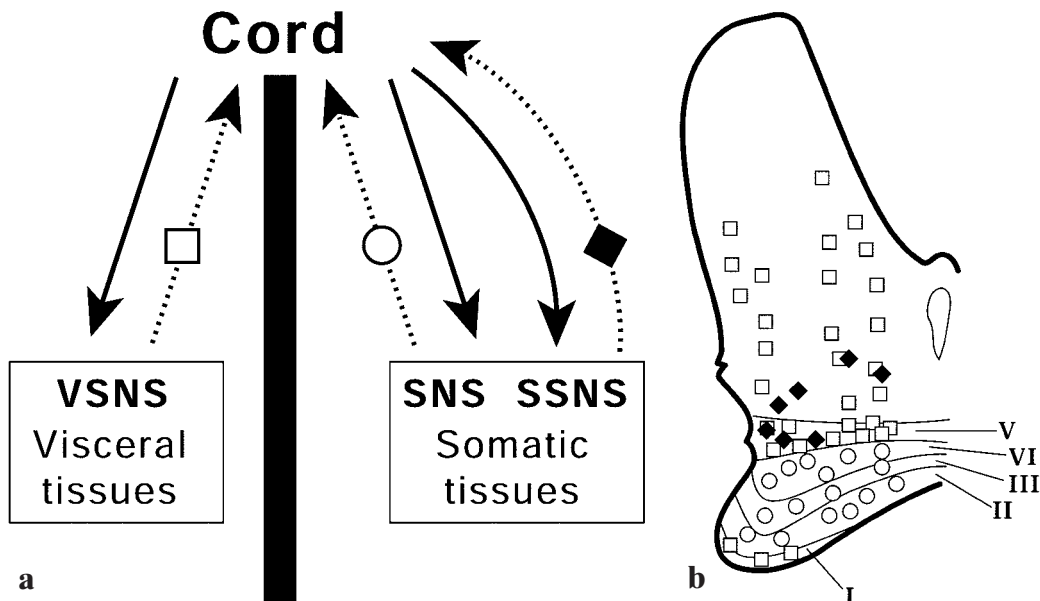


FIG. 6. – Schematics of proposed configuration of peripheral nervous system and its central terminations, illustrating some of the principles of CNS neural convergence of peripheral neural input, and explaining in part the mechanism of referred pain. a) Efferent pathways (solid arrows), afferent pathways (dashed arrows), visceral tissue sympathetic afferent fibers (open square), somatic tissue somatic afferent fibers (open circle), and hypothesized somatic tissue sympathetic afferent fibers (solid diamond). Note the use of the same symbols and meanings in figure b.

(VSNS=visceral sympathetic nervous system; SNS=somatic nervous system; SSNS=somatic sympathetic nervous system). b) Points of termination of visceral and somatic afferent fibers on cord neurons within dorsal and ventral gray matter of right spinal hemicord gray matter (ventral: top; dorsal: bottom; right hemicord to reader's left). Note overlapping regions covered by squares and diamonds that theoretically result in a central nervous system convergence of afferent fibers from divergent origins (i.e., peripheral visceral and somatic neural fiber CNS convergence). (I-V=laminae of dorsal horn gray matter of spinal cord; termination of somatic [somatic tissue somatic] afferent fibers on somatic cord neurons [open circles]; termination s of visceral [visceral tissue sympathetic] afferent fibers on visceral cord neurons [open squares]; terminations of somatic [proposed somatic tissue sympathetic] afferent fibers [alternate proposal: somatic tissue somatic fibers] on viscerosomatic cord neurons [solid diamonds])

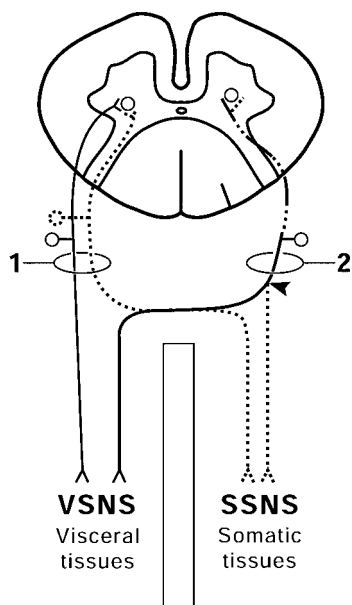


FIG. 7. – Schematic of proposed general organization of peripheral afferent somatic and sympathetic nervous systems illustrating CNS convergence of neural input from peripheral somatic and visceral tissues. Theoretically, referred pain may in part be a result of either of two possible mechanisms: convergence in spinal cord of separate fibers from visceral and somatic sources (1), or single convergence in spinal cord of bifurcating axons having diverging limbs within the visceral and somatic tissues (2). (1=dual afferent axon configuration; 2=bifurcating afferent axon configuration; visceral sympathetic afferent fibers [solid axons]; somatic sympathetic afferent fibers [dashed axons]; VSNS=visceral sympathetic nervous system; SSNA=somatic sympathetic nervous system; arrowhead=point of bifurcation).

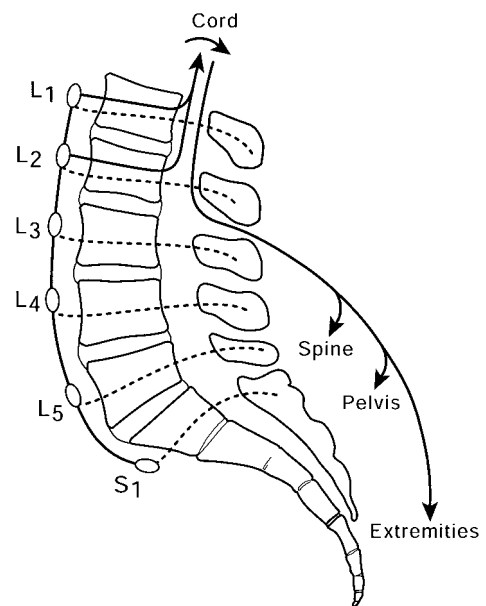


FIG. 8. – Schematic illustrating aberrant autonomic reflex arc. (manifestation: peripheral autonomic [sympathetic] dysfunction). The afferent limb (dashed lines) of the autonomic reflex arc is theoretically carried within ascending paraspinal sympathetic chain (open ovals). After synapse in spinal cord, the efferent limb is carried within peripheral ramifications (e.g., spine, pelvis, extremities) of somatic and/or sympathetic components of somatic spinal nerves (long multiheaded curved arrow).

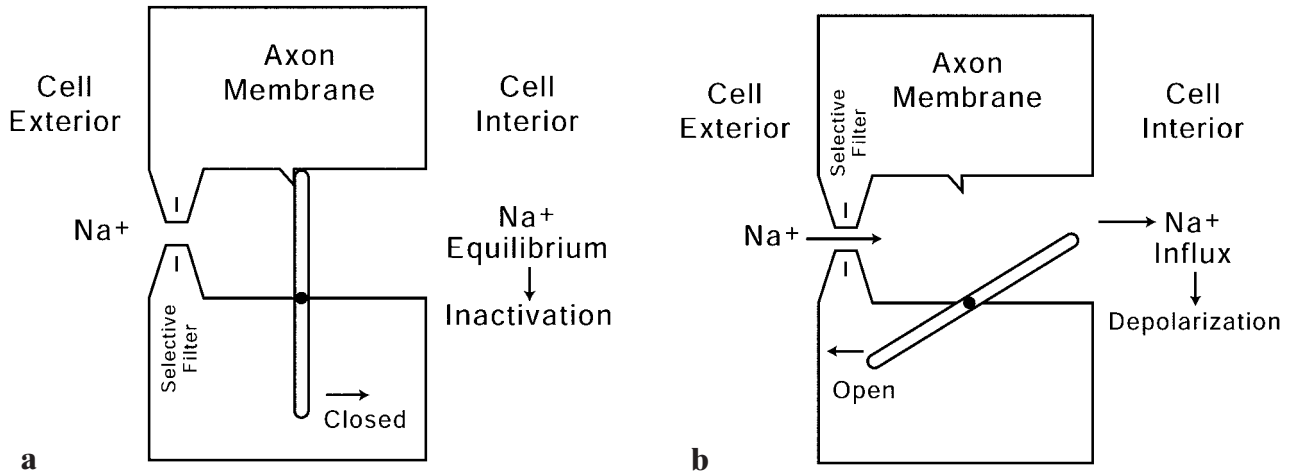


FIG. 9. – Schematics illustrating hypothetical mechanism of normal sodium ion channel function across axon membrane. a) When a sodium ion channel is closed, the passive influx of sodium ions into the cell intra-axonal space does not occur, the neuroelectrical voltage potential is maintained and no neuroelectrical activity takes place along or across the axon membrane. b) When a sodium ion channel is open, as in normal longitudinal neuroelectrical axon conduction (neuroelectrical impulse transmission), the passive influx of sodium ions into the intra-axonal space is facilitated resulting in depolarization across the axon membrane (NA+=sodium ions).

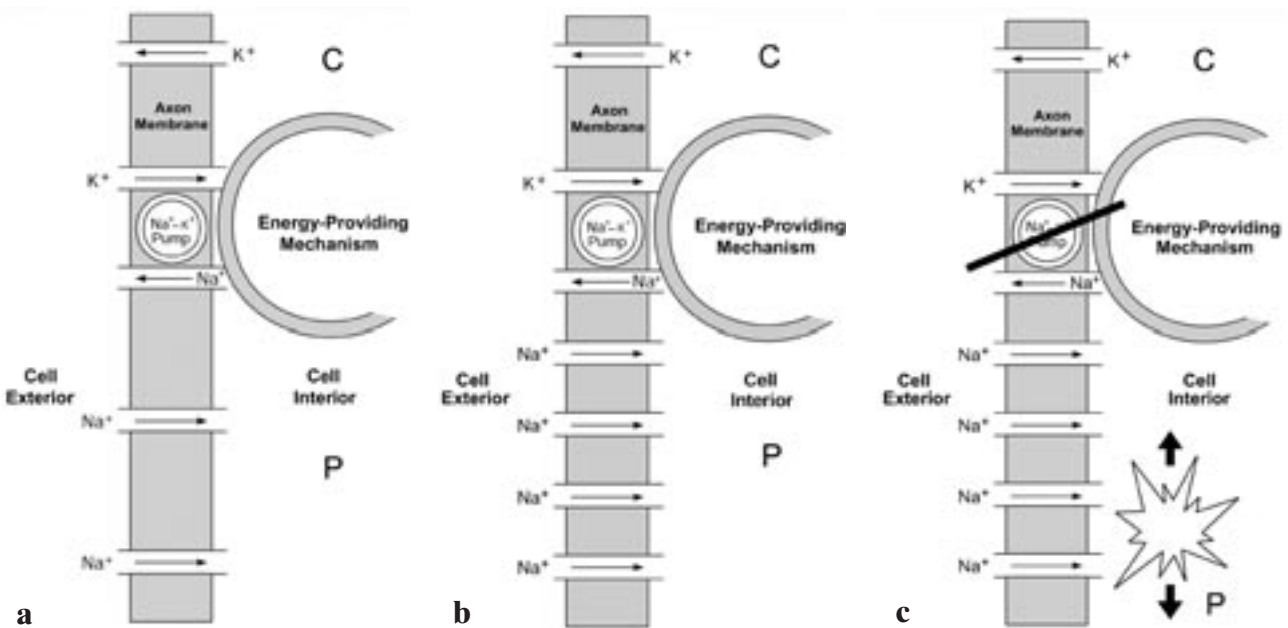


FIG. 10. – Schematics illustrating hypothetical mechanism of normal function and dysfunction in axon membrane resulting in axonal autodepolarization and ectopic neuroelectrical axon impulse generation (i.e., *radiating* radiculopathy). a) During normal neuroelectrical impulse transmission, sodium ion flow occurs into the axonal space, and potassium ions flow externally. Subsequently, after normal impulse transmission subsides, the active energy-requiring sodium-potassium pump, that maintains the neuroelectrical voltage potential across the axon membrane during inactivity, restores this ion voltage potential as the axon reaches a resting state. (NA+=sodium ions; K+=potassium ions; arrows in conduits=direction of flux in ion channels; C=central; P=peripheral). b) Unbalanced relationship between the sodium ion channels and the potassium pump. In this circumstance, the *functional* sodium ion channel spatial density in the axon membrane has increased without a consonant increase in the potential of the sodium-potassium pump to balance this phenomenon [compare with A]. This abnormal relationship theoretically overwhelms the sodium-potassium pump's ability to maintain the neuroelectrical voltage potential across the axon membrane resulting in autodepolarization (i.e., ectopic neuroelectrical axon impulse generation). (NA+=sodium ions; K+=potassium ions; arrows in conduits=direction of flux in ion channels; C=central; P=peripheral). c) The sodium-potassium pump itself may also be dysfunctional (oblique bar). Such a functional defect in the axon membrane constitutes an ectopic source (star burst) of neuroelectrical activity (i.e., within the intra-axonal space). Because the resulting aberrant neuroelectrical action impulse is transmitted in both directions (centrally and peripherally) along the axon (bold arrows), this phenomenon is theoretically partly responsible for pathologic efferent outflow peripheral nervous system (efferent somatic and autonomic fibers) involuntary expression (e.g., muscle spasm, autonomic dysfunction) and afferent inflow central nervous system (afferent somatic and autonomic fibers) conscious perception (e.g., radicular pain, paresthesias). (NA+=sodium ions; K+=potassium ions; arrows in conduits=direction of flux in ion channels; C=central; P=peripheral).

system dually ramifying within the visceral and the somatic tissues [73]. Understood in this way, referred actions and conscious perceptions are an expected if aberrant capacity of the autonomic (sympathetic) nervous system. Thus, while the ascending afferent lumbar *autonomic inflow diversion* accounts for extrasegmental CNS misregistration and patterns of mismatched and superimposed pain within the lumbosacral zones of Head, the actual primary referral seems to result from the mediation of the painful stimulus within the autonomic nervous system [10].

However, only so much can be understood within the framework of the peripheral nervous system, and thereafter CNS mechanisms of pain referral must be considered [18, 35]. Anatomic data suggest that somatic and visceral autonomic afferents may have the same or some of the same central connections at the level of the spinal cord, thalamus, and sensory cortex [13, 71, 88-90]. The *convergence theory* for the occurrence of referred pain states that because some of the same central pathways are shared by the converging visceral and somatic afferent autonomic systems, the CNS cannot precisely distinguish between the two origins of sensory input [72]. An ancillary hypothesis indicates that since the somatic tissues are normally continually consciously relaying stimuli, as opposed to the viscera, through a process of *pattern recognition*, the CNS attributes most of the segmental afferent inflow to somatic origins regardless of the true site of the stimulus [71, 82, 88]. There is little doubt, however, that some degree of modulation of afferent input from any peripheral source occurs at the level of the spinal cord and above [30, 90].

Thus some of the mechanisms for somatotopic referral of pain seem to lie at the level of the spinal cord and brain. As a further clarification, there seems to be a definite somatotopic organization of the spinal cord with regard to entering afferent fibers. Somatic afferent fibers largely terminate on neurons (i.e., *somatic* spinal cord neurons) within laminae II, III, and IV of the dorsal horn gray matter, while visceral afferent fibers terminate on neurons (i.e., *visceral* spinal cord neurons) in laminae I and V and within the ventral horn gray substance (*figure 6b*). However, there is a third population of cells located intermediately between these two groups (visceral and somatic) upon which some afferents terminate known as *viscerosomatic* spinal cord neurons. The rationale for this terminology is that these latter neurons are driven by afferent stimuli from both the somatic as well as the visceral tissues [71].

A complimentary theory to the foregoing for referred pain considers the possibility of bifurcating peripheral sympathetic afferent fibers, with one distal limb entering the visceral tissues while the other ramifies within the somatic tissues (*figure 7*) [3, 13, 15, 66]. Nevertheless, the important concept is still that of convergence of afferent impulses from different regions upon the same viscerosomatotopic registration area (or neuron) of the CNS, either primarily or via connecting interneurons. This may cause a false mental image of the localization of a sensory event. In context there-

fore, pain referred to the peripheral tissues (e.g., zones of Head) from a primary stimulus source such as the spine, does not have its stimulus origin in the area of conscious perception (i.e., zones of Head). This definition of central pain perception indicates that referred pain fields are thus wrongly *imagined* by the higher cognitive centers of the CNS in part because of afferent CNS sensory impulse *convergence*.

Autonomic nervous system function, however, is not confined to the conscious perception of painful stimuli. This network also has a major role in the mediation of unconscious normal autonomic function via autonomic reflex arcs occurring at the level of the spinal cord, which in turn are influenced by higher CNS levels [13, 39, 41, 88, 90]. Just as the conscious perception of pain may be spatially misregistered, so too may be various autonomic functions. Current understanding suggests that somatic as well as autonomic fibers both excite or otherwise share the same interneurons within the spinal cord [13]. Aberrant autonomic reflex arcs resulting in referred autonomic dysfunction of spinal column origin might be represented in the form of aberrant centrifugal vasomotor, pilomotor, and sudomotor activity perhaps within the zones of Head [71]. In addition to these positive sympathetic effects, reverse or paradoxical effects might be observed, presumably due to pre- and/or postsynaptic efferent inhibition by polysynaptic, polyaxonal afferent spinal cord input [88, 90].

However, these findings are seemingly minor, and are overshadowed by the manifestations of referred pain. Apparently, then, such autonomic dysfunction is often disregarded clinically. These phenomena

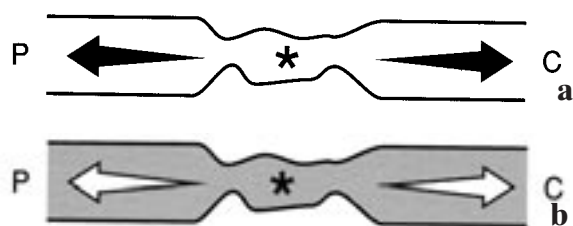


FIG. 11. – Schematics illustrating spontaneous ectopic neuroelectrical activity resulting in peripheral (labeled P) and central (labeled C) manifestations of referred pain. (a) Spontaneous ectopic neuroelectrical impulse (asterisk) originating in injured afferent axon (open channel: somatic or autonomic). The aberrant impulse (solid arrows) propagates away from the site of spontaneous depolarization, both centrally as well as peripherally (central manifestations: well localized pain perception referred signs and symptoms) (peripheral manifestation: sympathetic dystrophy [?]). (b) Spontaneous ectopic neuroelectrical impulses (asterisk) originating in injured efferent axon (shaded channel: somatic or autonomic). The aberrant impulse (open arrows) propagates away from the site of spontaneous depolarization, both peripherally as well as centrally (peripheral manifestations: skeletal muscle spasm; autonomic effector dysfunction).

may be more common than realized, and could perhaps be elicited with greater frequency and meaning if subjects were carefully scrutinized for these manifestations at the time of clinical examination.

Somatic muscle spasm can also possibly be associated with autonomic function/dysfunction [13, 22, 32, 71, 90]. Skeletal muscle spasm, which may become a painful process in and of itself, is in part theoretically accomplished by an aberrant reflex arc, similar to that of the autonomic reflex dysfunction discussed earlier. Thus, referred reflex somatic muscle spasm in the lumbosacral myotome, known as a *viscerosomatic reflex*, may account for clinically significant symptomatology [39]. The spasm itself could be produced by an arrest of the usual negative feedback mechanisms that ordinarily affect muscular contraction, because the stimulus does not originate within the area of the effect (i.e., the lumbosacral zone of

Head), but instead from a distant referral source (i.e., the spine). Alternately, unopposed positive feedback mechanisms may be responsible for the muscle spasm for similar reasons [88].

In all such autonomic reflex dysfunction, the afferent neural limb eventually enters the paraspinal sympathetic plexus. As previously discussed, largely because of the ascending autonomic inflow diversion (often entering at or above the L-2 segmental level) and because of the peculiarities of the autonomic (sympathetic) nervous system (both in its central and peripheral ramifications), there may be a spatial mismatching of otherwise normal autonomic afferent/efferent function, causing the efferent effector limb of the arc to occur in the peripheral somatome (*figure 8*). This autonomic dysfunction, an aberrant *somatosympathetic* (or *sympathosomatic*) reflex, might include any one or combination of dermal

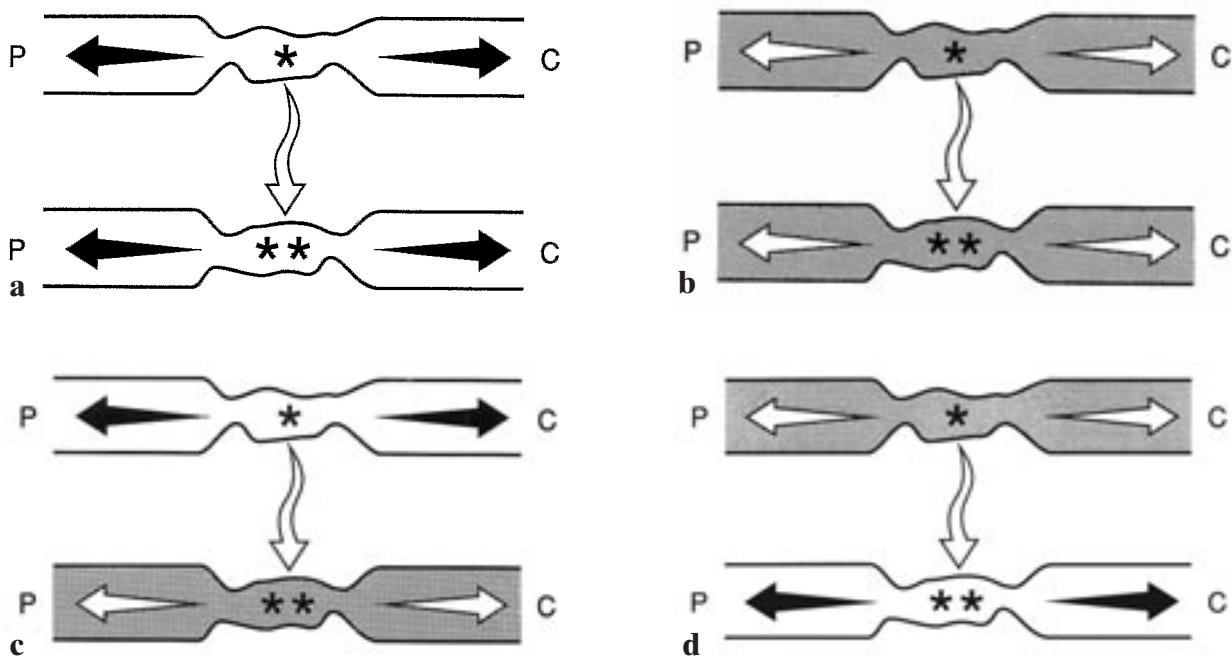


FIG. 12. – Schematics illustrating spontaneous ectopic neuroelectrical activity resulting in ephaptic axo-axonal transmission-stimulation between adjacent injured axons (wavy contoured channels). These phenomena could hypothetically occur between afferent axons (a), efferent axons (b), and between afferent and efferent axons (c, d). (manifestations: interaxonal ephaptic recruitment with multiplied peripheral and central effects and signs/symptoms). a) Spontaneous depolarization (single asterisk) originating in injured afferent axon (upper open channel: somatic or autonomic) results in a neuroelectrical impulse (single asterisk) that propagates away from site of ectopic origin (upper solid arrows). At the same time, ephaptic transmission (open serpentine arrow) axo-axonally results in neuroelectrical stimulation (double asterisk) of adjacent injured afferent axon (lower open channel: somatic or autonomic) acting as an ectopic receptor and effecting central (C) and peripheral (P) aberrant afferent axon impulse propagation (lower solid arrows). b) Spontaneous depolarization (single asterisk) originating in injured afferent axon (open channel: somatic or autonomic) results in a neuroelectrical impulse (single asterisk) that propagates away from site of ectopic origin (open straight arrows). At the same time, ephaptic transmission (open serpentine arrow) of axo-axonally results in neuroelectrical (direct neuroelectric exchange or ion-imbalance driven) stimulation (double asterisk) of adjacent injured efferent axon (shaded channel: somatic or autonomic) acting as an ectopic receptor and effecting central (C) and peripheral (P) aberrant efferent axon impulse propagation (open straight arrows). c) Spontaneous depolarization (single asterisk) originating in injured afferent axon (upper open channel: somatic or autonomic) results in a neuroelectrical impulse (single asterisk) that propagates away from site of ectopic origin (upper solid straight arrows). At the same time ephaptic transmission (open serpentine arrow) axo-axonally results in neuroelectrical (direct neuroelectric exchange or ion-imbalance driven) stimulation (double asterisk) of adjacent injured efferent axon (lower shaded channel: somatic or autonomic) acting as ectopic receptor and effecting central (C) and peripheral (P) aberrant afferent axon impulse propagation (lower open straight arrows). d) Spontaneous depolarization (single asterisk) originating in injured efferent axon (upper shaded channel: somatic or autonomic) results in ectopic neuroelectrical impulse (single asterisk) that propagates away from site of ectopic origin (open straight arrows). At the same time, ephaptic transmission (open serpentine arrow) axo-axonally results in a neuroelectrical (direct neuroelectric exchange or ion-imbalance driven) stimulation (double asterisk) of adjacent injured afferent axon (lower open channel: somatic or autonomic) acting as ectopic receptor and effecting central (C) and peripheral (P) aberrant afferent axon impulse propagation (solid straight arrows).

blushing, pallor, piloerection, diaphoresis, or somatic muscle spasm, reflecting genuine peripheral signs and symptoms within the lumbosacral zones of Head [71].

An additional possible referred phenomenon is the conscious perception of paresthasias of the somatic tissues within the zones of Head [22, 71]. The mechanism for this is presumably located at the level of the spinal cord and/or above, which unpredictably facilitates (hyperesthesia) or blocks (hypoesthesia) somatic afferent activity within the somatome in response to elevated paraspinal sympathetic chain afferent inflow [75].

Finally, signs and symptoms of general sympathetic outflow may occasionally play a role in the overall clinical complex during certain phases of spinal disease. For example, a large scale general sympathetic outflow is occasionally seen clinically and experimentally in conjunction with acute traumatic stimulation of vertebral elements. This results in varied viscerosomatic reactions, including a change in blood pressure, heart rate and respiratory rate, as well as elevations in alertness accompanied by nausea, all of which are not necessarily proportional to the severity and extent of the induced pain perceived by the patient [13, 22, 65].

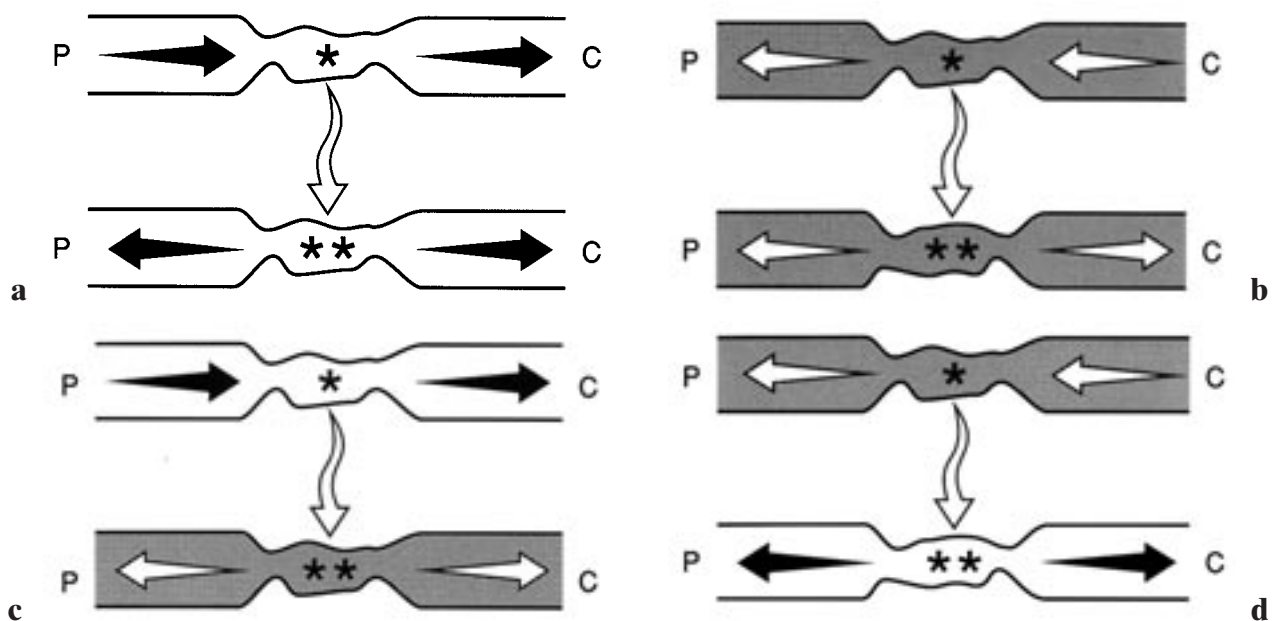


FIG. 13. – Schematics illustrating aberrant neuroelectrical activity driven by incoming or outgoing axon impulses and resulting in ephaptic axo-axonal transmission-stimulation between adjacent injured axons (wavy contoured channels). These phenomena could hypothetically occur between afferent axons (a), efferent axons (b), and between afferent and efferent axons (c, d). (manifestations: interaxonal neuroelectrical recruitment with multiplied peripheral and central effects and signs/symptoms) (manifestations: interaxonal ephaptic recruitment with multiplied peripheral and central effects and signs/symptoms). a) Peripherally originating (upper P) incoming neuroelectrical impulse (left-sided upper solid straight arrow) within injured afferent axon (upper open channel: somatic or autonomic) results in depolarization (single asterisk) at site of axon injury that propagates centrally (upper C) away from site of ectopic origin (right-sided upper solid straight arrow). At the same time, ephaptic transmission (open serpentine arrow) axo-axonally results in neuroelectrical (direct neuroelectric exchange or ion-imbalance driven) stimulation (double asterisk) of adjacent injured afferent axon (lower open channel: somatic or autonomic) acting as ectopic receptor and effecting central (lower C) and peripheral (lower P) aberrant afferent axon impulse propagation (lower solid straight arrows). b) Centrally originating (upper C) outgoing neuroelectrical impulse (right-sided upper open straight arrow) within efferent axon (upper shaded channel: somatic or autonomic) results in depolarization (single asterisk) at site of axon injury that propagates peripherally (upper P) away from site of ectopic origin (left-sided open straight arrow). At the same time, ephaptic transmission (open serpentine arrow) of electrical impulse axo-axonally causes neuroelectrical (direct neuroelectric exchange or ion-imbalance driven) stimulation (double asterisk) of adjacent injured efferent axon (lower shaded channel: somatic or autonomic) acting as ectopic receptor and effecting central (lower C) and peripheral (lower P) aberrant efferent axon impulse propagation (lower open straight arrows). c) Peripherally originating (upper P) incoming neuroelectrical impulse (left-sided upper solid straight arrow) within afferent axon (upper open channel: somatic or autonomic) results in depolarization (single asterisk) at site of axon injury that propagates centrally (upper C) away from site of ectopic origin (right-sided upper solid straight arrow). At the same time, ephaptic transmission (open serpentine arrow) of electrical impulse axo-axonally results in neuroelectrical (direct neuroelectric exchange or ion-imbalance driven) stimulation (double asterisk) of adjacent injured efferent axon (lower shaded channel: somatic or autonomic) acting as ectopic receptor and effecting central (lower C) and peripheral (lower P) aberrant afferent axon impulse propagation (lower open straight arrows). d) Centrally originating (upper C) outgoing neuroelectrical impulse (right-sided upper open straight arrow) within efferent axon (upper shaded channel: somatic or autonomic) results in depolarization (single asterisk) at site of axon injury that propagates peripherally (upper P) away from site of ectopic origin (left-sided upper open straight arrow). At the same time, ephaptic transmission (open serpentine arrow) axo-axonally causes stimulation (double asterisk) of adjacent injured afferent axon (lower open channel: somatic or autonomic) acting as ectopic receptor and effecting central (lower C) and peripheral (lower P) aberrant afferent axon impulse propagation (lower solid straight arrows).

ANATOMY OF CENTRIPETALLY/CENTRIFUGALLY RADIATING SPINAL SYNDROMES

On a yet more elemental level, if because of a nonspecific pathologic influence upon a spinal nerve root or nerve [14, 40, 52, 60], the geometry of the cell membrane of the axon and its sodium ion channels changes so that the functional channel density increases, the otherwise normal ion voltage potential equilibrium across the membrane may be disrupted [17]. The flow of normal ionic currents and the maintenance of the normal ion voltage potential across the axon membrane are in part dependent upon the functional sodium channel density within a given axon membrane area (itself a manifestation in part of the ion channel stability

of the membrane) (figure 9). Theoretically, if the functional sodium ion channel density per square area escalates (i.e., too many overfunctioning sodium ion channels per square area), the influx of sodium ions into the cell cannot be offset, as it normally is by the sodium-potassium pump mechanism [17]. The passive influx (by the sodium ion channels) out-paces the active efflux (by the sodium-potassium pump); for this reason the cell membrane in effect autodepolarizes producing an ectopic bidirectional action potential within the injured axon radiating away from the site of origin of the initial membrane depolarization (i.e., neural insult). The CNS (cerebral sensory cortex) interprets this neuroelectrical signal (incoming within appropriate afferent fibers) as pain and paresthe-

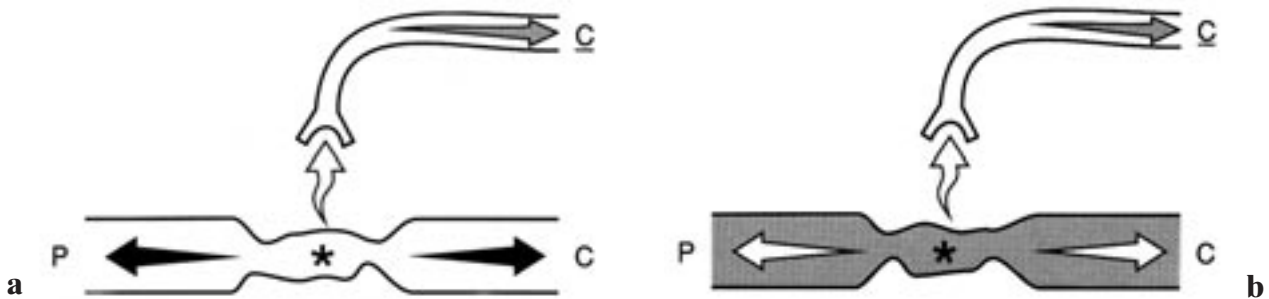


FIG. 14. – Schematics illustrating spontaneous ectopic neuroelectrical activity resulting in ephaptic transmission between injured axons (wavy contoured channels) and afferent *nervi nervorum* (open bifid channels). These phenomena could hypothetically occur in spinal dorsal roots (a), ventral roots (b), or in combined spinal nerves (a and b). (manifestations: magnified *local* pain in the distribution of the somatic *nervi nervorum*; magnified autonomic afferent-efferent reflex phenomena in the distribution of the sympathetic *nervi nervorum*). a) Spontaneous depolarization (single asterisk) originating in injured afferent axon (lower open channel: somatic or autonomic) results in neuroelectrical impulse (solid straight arrows) that propagates centrally (C) and peripherally (P) away from site of ectopic origin. At the same time, ephaptic transmission (open serpentine arrow) axo-axonally causes stimulation of normal or injured (sensitized) receptor (open bifid channel: somatic or autonomic) of afferent *nervi nervorum* effecting central (C) aberrant afferent axon impulse propagation (stippled arrow). b) Spontaneous depolarization (single asterisk) originating in injured efferent axon (lower shaded channel: somatic or autonomic) results in neuroelectrical impulse (open straight arrows) that propagates centrally (C) and peripherally (P) away from site of ectopic origin. At the same time, ephaptic transmission (open serpentine arrow) axo-axonally causes stimulation of normal or injured (sensitized) receptor (open bifid channel: somatic or autonomic) of afferent *nervi nervorum* effecting central (C) aberrant afferent axon impulse propagation (stippled arrows).

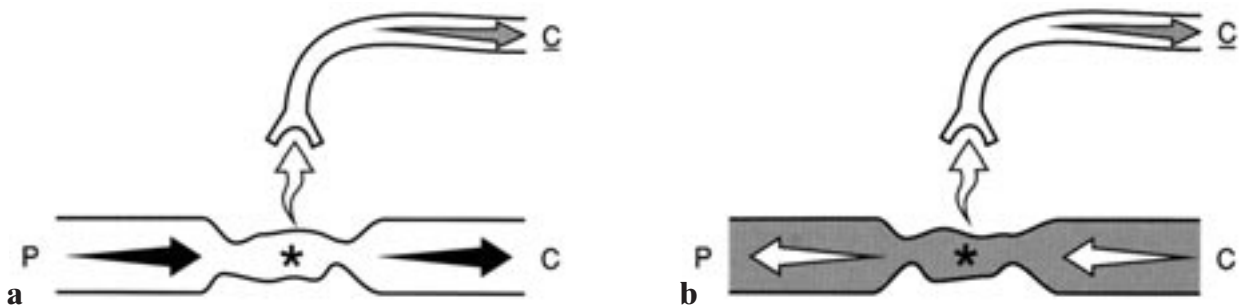


FIG. 15. – Schematics illustrating ectopic neurogenic activity driven by incoming or outgoing somatic or autonomic axon impulses and resulting in ephaptic axo-axonal transmission-stimulation between injured axon (wavy contoured channels) and afferent somatic or autonomic *nervi nervorum* (open bifid channels). These phenomena could hypothetically occur in spinal dorsal roots (a), ventral roots (b), or in combined spinal nerves (a and b). (manifestations: magnified *local* pain in the distribution of the somatic *nervi nervorum*; magnified autonomic afferent-efferent reflex phenomena in the distribution of the sympathetic *nervi nervorum*). a) Incoming neuroelectrical impulse (solid straight arrows) within afferent axon (open channel: somatic or autonomic) results in depolarization (asterisk) at site of injured axon. At the same time, ephaptic transmission (open serpentine arrow) axo-axonally causes stimulation of normal or injured (sensitized) receptor (open bifid channel: somatic or autonomic) of afferent *nervi nervorum* and effects central (C) aberrant afferent axon impulse propagation (stippled arrow). b) Outgoing neuroelectrical impulse (open straight arrows) within efferent axon (open channel: somatic or autonomic) results in depolarization (asterisk) at site of injured axon. At the same time, ephaptic transmission (open serpentine arrow) axo-axonally causes stimulation of normal or injured (sensitized) receptor (open bifid channel: somatic or autonomic) of afferent *nervi nervorum* and effects central (C) aberrant afferent axon impulse propagation (stippled arrow).

sias, a sign of involuntary muscular activity, or as a signal of/for autonomic action. In this manner axons in and of themselves may become mechano- and chemosensitive ectopic sources of pathologic neuroelectrical activity resulting in abnormal clinical expression and conscious perception. This is believed to be the pathophysiological basis for the so-called radiating radiculopathy.

Because of the presence of this ectopic axonal pacemaker, the transmission of normal incoming or outgoing neuroelectrical impulses occurring in, and adjacent to, fibers with pathologically altered axon membranes may also theoretically result in pain, paresthesias and somatic-autonomic dysfunction that similarly originate at the level of the ectopic source of activity. This aberrant impulse coupling is believed to take place because of abnormal interaxonal cross-stimulation based on chemical, neurochemical and/or *ephaptic* (direct neuroelectrical exchange) factors [17, 25, 68]. Theoretically this cross-stimulation is responsible for abnormal links within and between the somatic and autonomic fibers within these two systems. In this way the resultant proximal and distant propagation may occur within axons that are anatomically unrelated to the origin of the initial electrical transmission. In addition, a *recruitment* phenomenon may take place in this circumstance whereby a single ectopic neuroelectrical event may be responsible for firing within a large group of regional axons.

Experiments support the concept that focal neural injury can act as both an ectopic intrinsic stimulus as well as an ectopic receptor/transmitter [11, 12, 17, 25, 33, 50, 67-70, 75, 83, 85, 86]. Several possibilities are suggested by this condition. First, a chronically, repetitively injured afferent or efferent axon may act as a primary intrinsic ectopic pacemaker spontaneously discharging and initiating bidirectional intrinsic axonal impulse transmission (*figure 11*). Second, injured afferent or efferent axons acting as ectopic pacemakers may ephaptically (neuroelectrically) transmit neuroelectrical impulses extrinsically to ectopic axonal receptors in adjacent injured afferent and/or efferent axons (*figure 12*). This ephaptic transmission represents the type of interaxonal neuroelectrical cross-stimulation referred to above [17, 25, 67, 68, 75]. Third, because of chronic injury, afferent or efferent axons acting as primary ectopic neuroelectrical receptors may be driven by incoming peripheral afferent or outgoing central efferent somatic or autonomic axonal impulses; and, they may then secondarily ephaptically transmit neuroelectrical impulses to ectopic receptors in adjacent injured afferent and/or efferent somatic or autonomic axons (*figure 13*). Thus, as an example, efferent autonomic fibers neuroelectrically driving afferent somatic pain fibers in this way constitutes a relatively new theory of referred pain and dysfunction [17]. Fourth, because neural injury may result in part in increased receptor sensitivity, afferent or efferent axons acting as ectopic pacemakers may

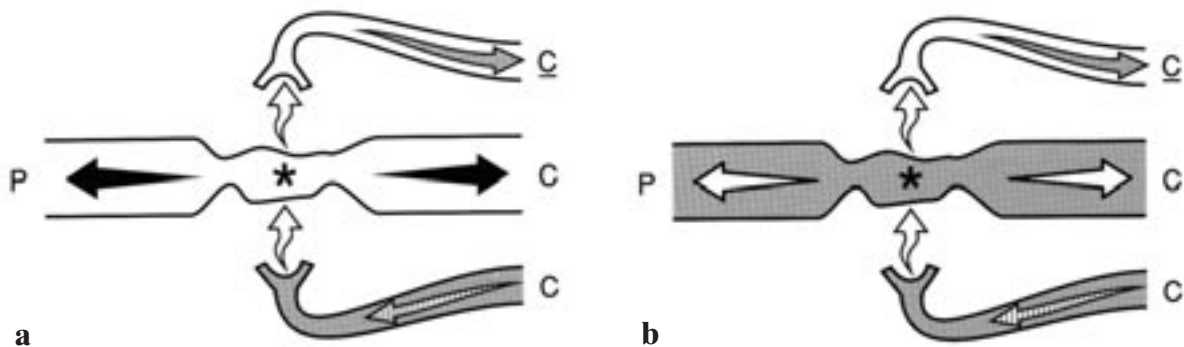


FIG. 16. – Schematics illustrating aberrant neuroelectrical activity driven by outgoing autonomic [sympathetic] efferent impulse resulting in ephaptic stimulation and transmission respectively between autonomic efferent *nervi nervorum* (shaded bifid channels), an injured adjacent axon (wavy contoured channels) and the afferent somatic or autonomic *nervi nervorum* (open bifid channels). These phenomena could hypothetically occur in spinal dorsal roots (a), ventral roots (b), or in combined spinal nerves (a and b). (manifestations: magnified *local* pain in the distribution of the somatic *nervi nervorum*, driven by the autonomic nervous system; magnified autonomic afferent-efferent reflex phenomena in the distribution of the sympathetic *nervi nervorum*, driven by the autonomic nervous system [autonomic dysfunction, pain, muscle spasm (?)]; central and peripheral signs and symptoms driven by the autonomic nervous system [pain, muscle spasm, autonomic dysfunction]). a) Incoming neuroelectrical impulse (hatched arrow) within efferent autonomic [sympathetic] axon (shaded bifid channel) of the *nervi nervorum* results in ephaptic stimulation (lower open serpentine arrow) axo-axonally and depolarization (asterisk) at site of injured afferent axon (wavy contour, open channel: somatic or autonomic) acting as ectopic receptor and effecting central (C) and peripheral (P), aberrant afferent axon impulse propagation (solid straight arrows). At the same time, ephaptic transmission (upper open serpentine arrow) axo-axonally causes stimulation of normal or injured (sensitized) receptor (open bifid channel: somatic or autonomic) of afferent *nervi nervorum* and effects central (C) aberrant afferent axon impulse propagation (stippled arrow). b) Incoming neuroelectrical impulse (hatched arrow) within normal or injured efferent autonomic [sympathetic] axon (shaded bifid channel) of the *nervi nervorum* results in ephaptic stimulation (lower open serpentine arrow) axo-axonally and depolarization (asterisk) at site of injured efferent axon (wavy contour, shaded channel: somatic or autonomic) acting as ectopic receptor and effecting central (C) and peripheral (P) aberrant efferent axon impulse propagation (open straight arrows). At the same time, ephaptic transmission (upper open serpentine arrow) axo-axonally causes stimulation of normal or injured (sensitized) receptor (open bifid channel: somatic or autonomic) of afferent *nervi nervorum* and effects central (C) aberrant afferent axon impulse propagation (stippled arrow).

ephaptically drive injured afferent fiber terminations on nerves, the afferent *nervi nervorum* (figure 14) [17]. Fifth, afferent or efferent axons acting as ectopic transmitters may be driven by incoming peripheral afferent or outgoing central efferent axonal impulses that may secondarily transmit neuroelectrical impulses ephaptically to afferent somatic and autonomic fiber terminations on nerves, once again, the afferent *nervi nervorum* (figure 15). Sixth, autonomic efferent fiber terminations on nerves, the efferent sympathetic *nervi nervorum*, may drive afferent or efferent axons acting as ectopic receptors, and these may in turn transmit neuroelectrical impulse activity ephaptically to the afferent *nervi nervorum* (figure 16). This latter observation is yet another possible mode of local pain, referred pain, radicular pain, muscular dys-

function, and aberrant autonomic activity. It is by these mechanisms that pathologically peripherally driven, centrally driven, spontaneously generated, mechanically and chemically stimulated and ephaptically transmitted neuroelectrical activity can hypothetically occur at and near the site of neural injury. This thereby causes ectopic single fiber neuroelectrical phenomena and/or multifiber somatic-somatic, somatic-autonomic, autonomic-somatic or autonomic-autonomic aberrant *neuroelectrical coupling* [17]. The expression of this abnormal neurogenic activity may potentially result in bizarre combinations of subjective symptoms (e.g., pain, paresthesias) and objective signs (e.g., skeletal muscle spasm, sympathetic dysfunction).

Thus, otherwise normal peripheral sensory activity, centrally initiated voluntary muscle activity,

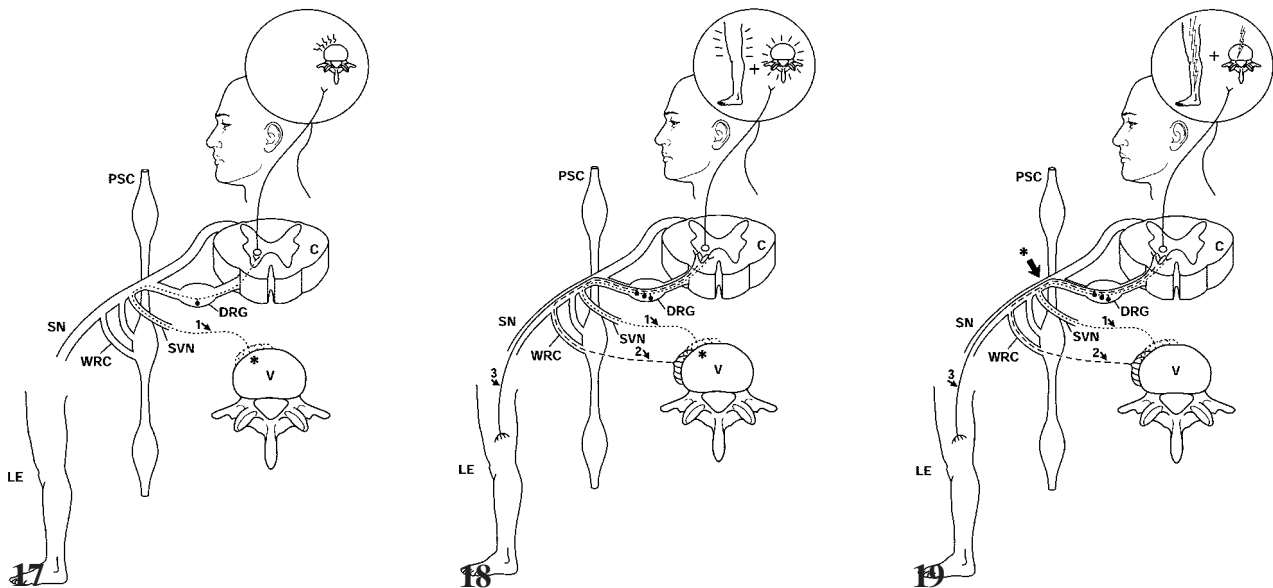


FIG. 17. – Schematic of *local* spinal syndrome. When a spinal element undergoes a noxious stimulation (asterisk), the direct neuroelectrical inflow of the sensory stimulus insures accurate mental localization of the stimulus from the site of the spine as imagined in the cerebral sensory cortex (upper right inset). (PSC=paraspinal sympathetic chain; C=spinal cord; SN=spinal nerve; WRC=white ramus communicans; DRG=dorsal root ganglion with sensory cell body giving rise to bipolar axonal processes; SVN=somatic [sensory] vertebral nerve [somatic afferent nerve]; LE=lower extremity; V=vertebral body; 1=somatic afferent sensory fiber from vertebra).

FIG. 18. – Schematic of *referred* (pseudoradicular) spinal syndrome. Because many of the spinal elements are served by autonomic (sympathetic) afferent fibers, neuroelectrical inflow from much of the lumbosacral region will traverse the ascending lumbosacral sympathetic diversion (i.e., paraspinal sympathetic chain) before entering the CNS. At the same time there may be a convergence of somatic and sympathetic fibers on the same neurons in the spinal cord. Among other reasons, this results in the mental illusion of a noxious influence originating in the lumbosacral spine (asterisk: arrow) to be recognized as ill-defined, deep low back, pelvic and proximal lower extremity pain and discomfort (upper right inset). (PSC=paraspinal sympathetic chain; C=spinal cord; DRG=dorsal root ganglion with sensory cell body giving rise to bipolar axonal processes; WRC=white ramus communicans; SVN=somatic [sensory] vertebral nerve branch [somatic afferent nerve]; SN=spinal nerve [mixed somatic-sympathetic nerve], V=vertebra, LE=lower extremity; 1=somatic afferent sensory fiber from vertebra; 2=sympathetic afferent sensory fiber from vertebra; 3=somatic or sympathetic afferent sensory fiber from lower extremity).

FIG. 19. – Schematic of *radiating* (radicular) spinal syndrome. Nonspecific noxious stimulation of a nerve root, spinal nerve, spinal nerve branch or dorsal root ganglion (asterisk: arrow) results in a radiating pain of a neuroelectrical nature within the affected axons. This may, in addition to radicular pain, generate skeletal muscle spasm, paresthesias, muscle weakness, reflex autonomic (sympathetic) dysfunction mentally imagined as radiating into the lower extremity, lumbosacral spine and pelvic structures (upper right inset). (PSC: paraspinal sympathetic chain, C: spinal cord, DRG: dorsal root ganglion with sensory cell body giving rise to bipolar axonal processes; WRC: white ramus communicans; SVN: somatic [sensory] vertebral nerve branch [somatic afferent nerve]; SN: spinal nerve; V: vertebra; LE: lower extremity; 1: somatic afferent sensory fiber from vertebra; 2: sympathetic afferent sensory fiber from vertebra; 3: somatic or sympathetic afferent sensory fiber from lower extremity)

(NOTE: The figures in this chapter have been modified from reference 43 with permission.)

centrally and reflexly driven sympathetic activity and somatic muscle movements resulting in stimulation of the affected nerve might cause neuropathic phenomena: significant pain and paresthesias, muscular dysfunction and autonomic derangement emanating from chronically injured spinal nerves/roots. These manifestations are various types of perceived *pathologic neurogenic pain* in that they are pain impulses that are generated within axons which are hyper-mechanosensitive and perhaps chemosensitive, they are pain impulses that are ectopic in origin (the primary impulses are not initiated within a normal neuroelectrical impulse generator), and they are pain impulses that are far larger in proportion and duration than would be anticipated to originate from the mechanical perturbation of a normal, uninflamed or uninjured axon or neural termination [11, 12, 21, 25, 33, 35, 49-51, 60-62, 67-70, 76, 83, 85, 86, 89]. Finally, the dorsal root ganglia have similarly been shown to have a potentially significant role in the genesis of centripitally/centrifugally radiating lumbosacral pain syndromes [34, 84].

CENTRAL PLASTICITY

A final and poorly understood, and relatively new hypothesis states that some degree of subacute and chronic overstimulation of the CNS neurons (spinal cord) such as by noxious stimuli may result in a type of plastic alteration of central tissue (*central plasticity*). This in turn is theorized to cause an impulse-sensitive CNS that may be more labile to future neuroelectrical input, and thus an increased mental perception of pain by the patient [18, 35].

CONCLUSION

The spinal column and related tissues are in part characterized by dual afferent and efferent innervation carried within both the somatic and autonomic nervous systems. Furthermore, the spinal part of the central nervous system (i.e., spinal cord), is linked to the periphery by a parallel tripartite peripheral nervous system consisting of the somatic tissue somatic nervous system, the somatic tissue autonomic nervous system, and the visceral tissue autonomic nervous system. This neuroanatomic arrangement is linked with related/parallel patterns of distribution of local and distant peripheral nerve fibers as well as their complex and sometimes converging central connections.

Thus, conscious perception and unconscious effects originating from the vertebral column, peri-vertebral soft tissues, and regional neural structures, although complex, have definite pathways represented in this network of innervation associated with intimately related or parallel components of the peripheral and central nervous systems.

Pathologic local, referred and radiating signs, symptoms and neurologic dysfunction may be observed and perceived by the patient in single or in superimposed combinations. This range of manifestations may mislead the patient and the physician

alike. The unique syndrome manifested by the patient can only hope to be understood by a careful understanding of these anatomic principles, the object being a more sophisticated and accurate linkage of signs and symptoms with specific spinal pathoanatomic alteration.

ACKNOWLEDGMENT

I thank D. Baker for the artwork.

REFERENCES

- [1] AHMED M, BJURHOLM A, KREICBERGS A, SCHULTZBERG M. Sensory and autonomic innervation of the facet joint in the rat lumbar spine. *Spine* 1993; 18: 2121-2126.
- [2] AUTEROCHE P. Innervation of the zygapophyseal joints of the lumbar spine. *Anat Clin* 1983; 5: 17-28.
- [3] BAHR R, BLUMBERG H, JANIG W. Do dichotomizing afferent fibers exist which supply visceral organs as well as somatic structures? A contribution to the problem of referred pain. *Neurosci Lett* 1981; 24: 25-28.
- [4] BOGDUK N, MUNRO RR. Posterior ramus-anterior ramus reflexes. *Proc Aust Physiol Pharmacol Soc* 1973; 4: 183.
- [5] BOGDUK N, LONG DM. The anatomy of the so-called "articular nerves" and their relationship to facet denervation in the treatment of low-back pain. *J Neurosurg* 1979; 51: 172-177.
- [6] BOGDUK N, TYNAN W, WILSON AS. The nerve supply to the human lumbar intervertebral discs. *J Anat* 1981; 132: 39-56.
- [7] BOGDUK N. Lumbar dorsal ramus syndrome. *Med J Aust* 1980; 2: 537-541.
- [8] BOGDUK N, WILSON AS, TYNAN W. The human lumbar dorsal rami. *J Anat* 1982; 134: 383-397.
- [9] BOGDUK N. The sources of low back pain. In: Jayson MIV, ed. *The lumbar spine and back pain*. Fourth Edition. Edinburgh, Churchill-Livingstone: 61-88, 1992.
- [10] BOGDUK N. The innervation of the lumbar spine. *Spine* 1983; 8: 286-293.
- [11] BOSTOCK H, SEARS TA. The internodal axon membrane: electrical excitability and continuous conduction in segmental demyelination. *J Physiol* 1978; 280: 273-301.
- [12] CALVIN WH, DEVOR M, HOWE JF. Can neuralgias arise from minor demyelination? Spontaneous firing, mechanosensitivity, and after discharge from conducting Axons. *Experimental Neurology* 1982; 75: 755-763.
- [13] CERVERO F. Visceral nociception: peripheral and central aspects of visceral nociceptive systems. *Philos Trans R Soc Lond* 1985; 8: 325-337.
- [14] DAHLIN LB, RYDEVIK, LUNDBORG G. Pathophysiology of nerve entrapments and nerve compression injuries. In: *Tissue Nutrition and Viability*. Hargens AR, ed. New York, Springer-Verlag: 135-160, 1986.
- [15] DALSGAARD CJ, YGGE J. Separate populations of primary sensory neurons project to the splanchnic nerve and thoracic spinal nerve rami of the rat. *MED BIOL* 1985; 63: 88-91.
- [16] DASS R. Sympathetic components of the dorsal primary divisions of human spinal nerves. *Anat Rec* 1952; 113: 493-501.
- [17] DEVOR M, RAPPAPORT ZH. Pain and the pathophysiology of damaged nerve. In: *Pain syndromes in neurology*. Fields HL, ed. Boston, Butterworths: 47-83, 1990.
- [18] DEVOR M. Central changes mediating neuropathic pain. In: *Proceedings of the Vth world congress of pain*. Dubner R, Gebhart GF, Bond MR, eds. Amsterdam, Elsevier Science Publishers BV: 114-128, 1988.
- [19] ECHLIN F. Pain responses on stimulation of the lumbar sympathetic chain under local anesthesia. *J Neurosurg* 1949; 6: 530-531.
- [20] EDGAR MA, GHADIALY JA. Innervation of the lumbar spine. *Clin Orthop* 1976; 115: 35-41.

- [21] EL MAHDI MA, ABDEL LATIF FY, JANKO M. The spinal nerve root "innervation", and a new concept of the clinico-pathological interrelations in back pain and sciatica. *Neurochirurgia* 1981; 24: 137-141.
- [22] FEINSTEIN B, LANGION JNK, JAMESON RM, SCHILLER F. Experiments on pain referred from deep somatic tissues. *J Bone Joint Surg [Am]* 1954; 36-A: 981-997.
- [23] FREEMONT AJ, PEACOCK TE, GOUPILLE P, HOYLAND JA, O'BRIEN J, JAYSON MIV. Nerve involved into diseased intervertebral disc in chronic back pain. *The Lancet* 1997; 350: 178-181.
- [24] FUKUI S, OHSETO K, SHIOTANI M, OHNO K, HIDETAKE K, YOSHIKAZU N. Distribution of referred pain from the lumbar zygapophyseal joints and dorsal rami. *Spine* 1997; 13: 303-307.
- [25] GARDNER WJ. Cross talk — the paradoxical transmission of a nerve impulse. *Arch Neurol* 1966; 14: 149-156.
- [26] GILLETTE RG, KRAMIS RC, ROBERTS WJ. Sympathetic activation of cat spinal neurons responsive to noxious stimulation of deep tissues in the low back. *Pain* 1994; 56: 31-42.
- [27] GRAY H. Anatomy of the human body. Philadelphia: Lea and Febiger, 1: 251-1254, 1264-1265, 1985.
- [28] GROEN GJ, BALJET B, DRUKKER J. The Innervation of the spinal dura mater: anatomy and clinical implications. *Acta Neurochir* 1988; 92: 39-46.
- [29] GROEN GJ, BALJET B, DRUKKER J. Nerves and nerve plexuses of the human vertebral column. *Am J Anat* 1990; 188: 282-296.
- [30] HANNINGTON-KIFF J. The modulation of pain. In: Disorders of the lumbar spine. Helfet AJ, Lee DMG, eds. Philadelphia, JB Lippincott: 120-136, 1978.
- [31] HEAD H. On disturbances of sensation with especial reference to the pain of visceral disease. *Brain* 1893; 16: 1-32.
- [32] HOCKADAY JM, WHITTY CW. Patterns of referred pain in the normal subject. *Brain* 1967; 90: 482-496.
- [33] HOWE JF, CALVIN WH, LOESER JD. Impulses reflected from dorsal root ganglia and from focal nerve injuries. *BRAIN RES* 1976; 116: 139-144.
- [34] HOWE JF, LOESER JD, CALVIN WH. Mechanosensitivity of dorsal root ganglia and chronically injured axons: a physiological basis for the radicular pain of nerve root compression. *Pain* 1977; 3: 25-41.
- [35] HUNT JL, WINKELSTEIN BA, RUTKOWSKI MD, WEINSTEIN JN, DELEO JA. Repeated injury to the lumbar nerve roots produces enhanced mechanical allodynia and persistent spinal neuroinflammation. *Spine* 2001; 26: 2073-2079.
- [36] IMAI S, HUKUDA S, MAEDA T. Dually innervating nociceptive networks in the rat lumbar posterior longitudinal ligaments. *Spine* 1995; 20: 2086-2092.
- [37] INMAN VT, SAUNDERS JB DE C. Referred Pain from skeletal structures. *J Nerv Ment Dis* 1944; 99: 660-667.
- [38] JACKSON HC, WINKELMAN RK, BICKEL WH. Nerve endings in the human lumbar spinal column and related structures. *J Bone Joint Surg [Am]* 1966; 48A: 1272-1281.
- [39] JANIG W. The autonomic nervous system. In: Fundamentals of neurophysiology. Schmidt RF, ed. New York, Springer-Verlag: 216-269, 1985.
- [40] JAYSON MIV. The role of vascular damage and fibrosis in the pathogenesis of nerve root damage. *Clin Orthop Rel Res* 1992; 279: 40-48.
- [41] JENKINS TW. Physiology of spinal nerves. In: Functional mammalian neuroanatomy. Philadelphia, Lea and Febiger: 107-133, 1978.
- [42] JINKINS JR, WHITTEMORE AR, BRADLEY WG. The anatomic basis of vertebrogenic pain and the autonomic syndrome associated with lumbar disk extrusion. *AJNR* 1989; 10: 219-231; *AJR* 1989; 152: 1277-1289.
- [43] JINKINS JR. The pathoanatomic basis of somatic and autonomic syndromes originating in the lumbosacral spine. *Neuro Clin Nor Am* 1993; 3: 443-463.
- [44] JINKINS JR. The pathoanatomic basis of somatic, autonomic and neurogenic syndromes originating in the lumbosacral spine. *Rivista di Neuroradiol* 1995; 8 (S): 35-51.
- [45] JINKINS JR. The pathoanatomic basis of somatic, autonomic and neurogenic syndromes originating in the lumbosacral spine. In: Clinical anatomy and management of low back pain. Giles LGF, Singer K, eds. Oxford, England, Butterworth-Heinemann: 255-272, 1997.
- [46] KAPLAN EB. Recurrent meningeal branch of the spinal nerves. *Bull Hosp JT Dis Orthop Inst* 1947; 8: 108-109.
- [47] KELLGREN JH. On the distribution of pain arising from deep somatic structures with chords of segmental pain areas. *Clin Sci Mo Med* 1939; 4: 35-46.
- [48] KORKALA O, GRÖENBLAD M, LIESE P, KARAHARJU E. Immunohistochemical demonstration of nociceptors in the ligamentous structures of the lumbar spine. *Spine* 1985; 10: 156-157.
- [49] KUSLICH SD, ULSTROM L, MICHAEL CJ. The tissue origin of low back pain and sciatica: a report of pain response to tissue stimulation during operations of the lumbar spine using local anaesthesia. *Orthop Clin Nor Am* 1991; 22: 181-187.
- [50] LEHMANN HJ, ULE G. Electrophysiological findings and structural changes in circumspect inflammation of peripheral nerves. *Prog Brain Res* 1964; 6: 169-173.
- [51] LOW PA. Endoneurial potassium is increased and enhances spontaneous activity in regenerating mammalian nerve fibers — implications for neuropathic positive symptoms. *Muscle and Nerve* 1985; 8: 27-33.
- [52] LUNDBORG G, DAHLIN LB. Pathophysiology of nerve compression. In: Nerve compression syndromes. Szabo RM, ed. Thorofare, NJ, Slack, Inc.: 15, 1989.
- [53] MARKS R. Distribution of pain provoked from lumbar facet joints and related structures during diagnostic spinal infiltration. *Pain* 1989; 39: 37-40.
- [54] MCCALL IW, PARK WM, O'BRIEN JP. Induced pain referral from posterior lumbar elements in normal subjects. *Spine* 1979; 4: 442-446.
- [55] MOONEY V, ROBERTSON J. The facet syndrome. *Clin Orthop* 1976; 115: 149-156.
- [56] MORINAGA T, TAKAHASHI K, YAMAGATA M, CHIBA T, TANAKA K, TAKASHI Y, NAKAMURA SI, SUSEKI K, MORIYA H. Sensory innervation to the anterior portion of lumbar intervertebral disc. *Spine* 1996; 21: 1848-1851.
- [57] MURPHY RW. Nerve roots and spinal nerves in degenerative disk disease. *Clin Orthop Related Res* 1977; 129: 46-60.
- [58] NAKAMURA S, TAKAHASHI K, TAKAHASHI Y, YAMAGATA M, MORIYA H. The afferent pathways of discogenic low back pain. *J Bone Joint Surg [Br]* 1996; 78-B: 606-612.
- [59] NAKAMURA S, TAKAHASHI K, TAKAHASHI Y, MORINAGA T, SHIMADA Y, MORIYA H. Origin of nerves supplying the posterior portion of lumbar intervertebral discs in rats. *Spine* 1996; 21: 917-924.
- [60] OCHOA J. Nerve fiber pathology in acute and chronic compression. In: Management of peripheral nerve problems. Omer GE, Spinner M, eds. Philadelphia, WB Saunders: 487, 1980.
- [61] OLMARKER K, RYDEVIK B, NORDBORG C. Autologous nucleus pulposus induces neurophysiologic and histologic changes in porcine cauda equina nerve roots. *Spine* 1993; 18: 1425-1432.
- [62] OLMARKER K, MYERS RR. Pathogenesis of sciatic pain: role of herniated nucleus pulposus and deformation of spinal nerve root and dorsal root ganglion. *Pain* 1998; 78: 99-105.
- [63] PARIS SV. Anatomy as related to function and pain. *Orthop Clin North Am* 1983; 14: 475-489.
- [64] PARKE WW. Development of the spine. In: The Spine. Rothman RH, Simeone FA, eds. Philadelphia, Saunders: 1-17, 1982.
- [65] PEDERSEN DL, BLUNCK CFJ, GARDNER E. The anatomy of lumbosacral posterior rami and meningeal branches of spinal nerves (sinu-vertebral nerves). *J Bone Joint Surg [Am]* 1956; 38-A: 377-391.
- [66] PIERAU F, FELLNER G, TAYLOR DCM. Somato-visceral convergence in cat dorsal root ganglion neurones demon-

- trated by double-labeling with fluorescent tracers. *Brain Res* 1984; 321: 63-70.
- [67] RAMON F, JOYNER RW, MOORE JW. Ephaptic transmission in squid giant axons. *Biophys J* 1976; 16: 26a.
- [68] RASMINSKY M. Ectopic-generation of impulses and cross-talk in spinal nerve roots of "dystrophic" mice. *Ann Neurol* 1978; 3: 351-357.
- [69] RASMINSKY M. Physiology of conduction in demyelinated axons. In: The physiology and pathobiology of axons. Waxman SG, ed. New York, Raven: 361-376, 1978.
- [70] RASMINSKY M. Ectopic generation of impulses in pathological nerve fibers. In: Nerve repair and regeneration — its clinical and experimental basis. Jewett DL, McCarroll HR, eds. St. Louis, Mosby: 178-195, 1980.
- [71] RUCH TC. Pathophysiology of pain. In: Physiology and biophysics. Ruch TC, Patton HD, eds. Philadelphia, Saunders: 508-531, 1982.
- [72] RUCKER HK, HOLLOWAY JA. Viscerosomatic convergence onto spinothalamic tract neurons in the cat. *Brain Res* 1982; 243: 155-157.
- [73] SAMEDA H, TAKAHASHI Y, TAKAHASHI K, CHIBA T, OHTORI S, MORIYA H. Primary sensory neurons with dichotomizing axons projecting to the facet joint and the sciatic nerve in rats. *Spine* 2001; 26: 1105-1109.
- [74] SEKINE M, YAMASHITA T, TAKEBAYASHI T, SAKAMOTO N, MINAKE Y, ISHII S. Mechanosensitive afferent units in the lumbar posterior longitudinal ligament. *Spine* 2001; 26: 1516-1521.
- [75] SELTZER Z, DEVOR M. Ephaptic transmission in chronically damaged peripheral nerves. *Neurology* 1979; 29: 1061-1064.
- [76] SMYTH JM, WRIGHT VJ. Sciatica and the intervertebral disk. An experimental study. *J Bone Joint Surg* 1958; 40 [A]: 1401-1418.
- [77] STILWELL DL. The nerve supply of the vertebral column and its associated structures in the monkey. *Anat Rec* 1956; 125: 139-169.
- [78] SUSEKI K, TAKAHASHI Y, TAKAHASHI K, CHIBA, TANAKA K, MORIYA H. CGRP-immunosuppressive nerve fibers projecting to lumbar facet joints through the paravertebral sympathetic trunk in tracts. *Neuroscience Letters* 1996; 221: 41-44.
- [79] SUSEKI K, TAKAHASHI Y, TAKAHASHI K et al. Innervation of the lumbar facet joints: origins and functions. *Spine* 1997; 22: 477-485.
- [80] SUSEKI K, TAKAHASHI Y, TAKAHASHI K, CHIBA T, YAMAGATA M, MORIYA H. Sensory nerve fibers from lumbar intervertebral discs pass through rami communicantes: a possible pathway for discogenic low back pain. *J Bone Joint Surg [Br]* 1998; 80-B: 737-742.
- [81] TAKAHASHI Y, NAKAJIMA Y, SAKAMOTO T, MORIYA H, TAKAHASHI K. Capsaicin applied to rat lumbar intervertebral disc causes extravasation in the groin skin: a possible mechanism of referred pain of the intervertebral disc. *Neuroscience Letters* 1993; 161: 1-3.
- [82] TAKAHASHI Y, MORINAGA T, NAKAMURA S-I, SUSEKI K, TAKAHASHI K, NAKAJIMA Y. Neural connection between the ventral portion of the lumbar intervertebral disc and the groin skin. *J Neurosurg* 1996; 85: 323-328.
- [83] WALL PD, WAXMAN S, BASBAUM AL. Ongoing activity in peripheral nerve injury discharge. *Exp Neurol* 1974; 45: 576-589.
- [84] WALL PD, DEVOR M. Sensory afferent impulses originate from dorsal root ganglia as well as from the periphery in normal and nerve injured rats. *Pain* 1983; 17: 321-339.
- [85] WALLIS WE, VAN POZNAK A, PLUM F. Generalized muscular stiffness, fasciculations and myokymia of peripheral nerve origin. *Arch Neurol* 1970; 22: 430-439.
- [86] WETTSTEIN A. The origins of fasciculations in motorneuron disease. *Neurology* 1977; 27: 357-358.
- [87] WIBERG G. Back pain in relation to the nerve supply of the intervertebral disc. *Acta Orthop Scand* 1949; 19: 211-221.
- [88] WILLIS WD, GROSSMAN RG. The spinal cord. In: Medical neurobiology. St. Louis, Mosby: 80-115, 1973.
- [89] WILLIS WD, Grossman RG. Sensory systems. In: Medical neurobiology. St. Louis, Mosby: 227-272, 1973.
- [90] WYKE B. The neurology of low back pain. In: The lumbar spine and back pain. Jayson MIV, ed. New York, Churchill-Livingstone: 56-99, 1987.
- [91] YAMASHITA T, MINAKI Y, OOTA I, YOKOGUSHI K, ISHII S. Mechanosensitive afferent units in the lumbar intervertebral disc and adjacent muscle. *Spine* 1993; 18: 2252-2256.