

GRADING PELVIC PROLAPSE AND PELVIC FLOOR RELAXATION USING DYNAMIC MAGNETIC RESONANCE IMAGING

CRAIG V. COMITER, SANDIP P. VASAVADA, ZORAN L. BARBARIC, ANGELO E. GOUSSE, AND SHLOMO RAZ

ABSTRACT

Objectives. With significant vaginal prolapse, it is often difficult to differentiate among cystocele, enterocele, and high rectocele by physical examination alone. Our group has previously demonstrated the utility of magnetic resonance imaging (MRI) for evaluating pelvic prolapse. We describe a simple objective grading system for quantifying pelvic floor relaxation and prolapse.

Methods. One hundred sixty-four consecutive women presenting with pelvic pain ($n = 39$) or organ prolapse ($n = 125$) underwent dynamic MRI. The "H-line" (levator hiatus) measures the distance from the pubis to the posterior anal canal. The "M-line" (muscular pelvic floor relaxation) measures the descent of the levator plate from the pubococcygeal line. The "O" classification (organ prolapse) characterizes the degree of visceral prolapse beyond the H-line.

Results. The image acquisition time was 2.5 minutes per study. Each study cost \$540. In the pain group, the H-line averaged 5.2 ± 1.1 cm versus 7.5 ± 1.5 cm in the prolapse group ($P < 0.001$). The M-line averaged 1.9 ± 1.2 cm in the pain group versus 4.1 ± 1.5 cm in the prolapse group ($P < 0.001$). Incidental pelvic pathologic features were commonly noted, including uterine fibroids, ovarian cysts, hydroureter, urethral diverticula, and foreign body.

Conclusions. The HMO classification provides a straightforward and reproducible method for staging and quantifying pelvic floor relaxation and visceral prolapse. Dynamic MRI requires no patient preparation and is ideal for the objective evaluation and follow-up of patients with pelvic prolapse and pelvic floor relaxation. MRI obviates the need for cystourethrography, pelvic ultrasound, or intravenous urography and has become the study of choice at our institution for evaluating the female pelvis. UROLOGY 54: 454-457, 1999. © 1999, Elsevier Science Inc.

In the setting of significant vaginal prolapse, it is often difficult to differentiate among cystocele, enterocele, and high rectocele by physical examination alone. With uterine prolapse, the cervix and uterus often fill the entire introitus, making the diagnosis of concomitant pelvic prolapse difficult. Many of the current methods for evaluating pelvic prolapse and pelvic floor relaxation are invasive, poorly tolerated, or incomplete. However, accurate preoperative staging of pelvic prolapse and pelvic floor relaxation remains necessary for proper sur-

gical planning and to reduce the risk of recurrent prolapse.

Rapid-sequence dynamic magnetic resonance imaging (MRI) provides excellent visualization of the pelvic organs and musculofascial supportive structures. It is fast, noninvasive, does not use ionizing radiation, requires no patient preparation, and is relatively inexpensive. Our group has previously demonstrated the utility of MRI in visualizing the bladder neck and urethra and in evaluating stress urinary incontinence and pelvic prolapse.^{1,2} As dynamic MRI is a relatively new technique, no standardized classification and grading system is available for evaluating pelvic prolapse and pelvic floor relaxation with this modality. We propose a simple and objective grading system for describing, quantifying, and staging pelvic organ prolapse and pelvic floor relaxation using dynamic MRI.

From the Department of Urology, University of California, Los Angeles School of Medicine, Los Angeles, California

Reprint requests: Shlomo Raz, M.D., Department of Urology, University of California, Los Angeles School of Medicine, 924 Westwood Boulevard, Suite 520, Los Angeles, CA 90024

Submitted: February 9, 1999, accepted (with revisions): March 19, 1999

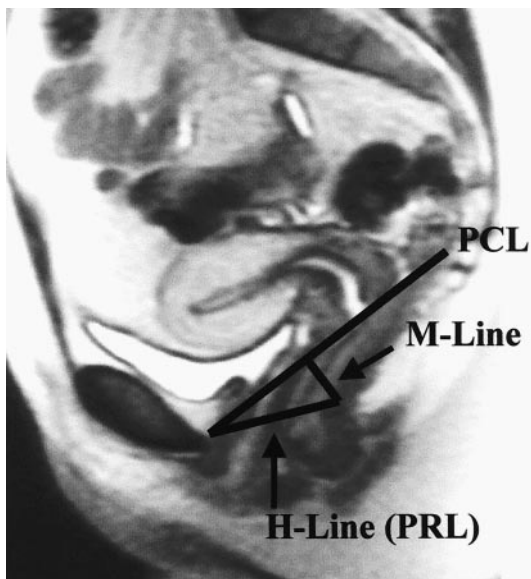


FIGURE 1. Dynamic HASTE sequence MRI in a patient without prolapse. H-line measures width of levator hiatus. M-line measures muscular pelvic floor relaxation (ie, descent of levator plate from pubococcygeal line [PCL]). PRL = puborectal line.

MATERIAL AND METHODS

From September 1997 to October 1998, 164 consecutive women (age 23 to 88 years) presenting with pelvic prolapse (n = 125) or with complaints other than stress incontinence or prolapse (pelvic pain, recurrent infections, or urethral pain; n = 39) underwent half-Fourier-acquisition single-shot turbo spin echo (HASTE) sequence MRI in a 1.5-Tesla magnet with phased array coils (Siemens) or single-shot fast spin echo (SSFSE) T₂-weighted sequence MRI in a 1.5-Tesla magnet (General Electric). These MRI sequences are equivalent, with similar image acquisition settings. Midsagittal and parasagittal cuts were obtained in the supine position, relaxed and with straining. Twenty-four static sagittal images were obtained in two sets of 8 seconds of breath holding (HASTE sequence) or 17 cuts, 1 second each, no breath holding (SSFSE sequence). Then, 5 midsagittal cuts were obtained with the patient relaxed and with straining.

Single, midsagittal cuts were obtained during 3 seconds of breath holding, both relaxed and during an increasing Valsalva maneuver. No pre-examination preparation or instrumentation was used. The images were looped as a cine stack for viewing and measuring the relationship among the mobile pelvic organs and fixed anatomic landmarks. In cases of high-grade prolapse, MRI of the ureters and kidneys was performed to assess for hydroureteronephrosis.

The size of the levator hiatus and degree of muscular pelvic floor relaxation and organ prolapse were measured (Fig. 1). The "H-line" (levator hiatus width) measures the distance from the pubis to the posterior anal canal. The "M-line" (muscular pelvic floor relaxation) measures the descent of the levator plate from the pubococcygeal line. The pubococcygeal line spans the distance from the pubis to the coccyx. The "O" classification (organ prolapse) describes the degree of visceral prolapse beyond the H-line. The degree of cystocele, urethrocele, rectocele, enterocele, and uterine descent were graded as 0 (none), 1 (minimal), 2 (moderate), and 3 (severe). All MRI images and cine loops were obtained and interpreted by a single radiologist (Z.B.) familiar with these techniques. All patients were evaluated with a complete history and physical

TABLE I. H-line (width of the levator hiatus), M-line (muscular pelvic floor relaxation), and O classification (organ prolapse) in symptomatic prolapse group vs. pelvic pain group

	Nonprolapse Group (n = 39)	Prolapse Group (n = 125)
H-line width (cm)	5.2 ± 1.1	7.5 ± 1.5
M-line width (cm)	1.9 ± 1.2	4.1 ± 1.5
Urethrocele (n)	3	95
Cystocele (n)	0	110
Enterocele (n)	1	42
Rectocele (n)	9	65
Vaginal cuff/uterine descent (n)	1	74

examination, including a detailed pelvic examination, by a single examiner (S.R.). In cases of voiding dysfunction or complex urinary incontinence, multichannel videourodynamic evaluation was performed.

RESULTS

The first set of images were volumetric sagittal cuts from left to right, used to locate the midsagittal plane at the level of the symphysis pubis and to survey the pelvic anatomy. The second set of images was obtained as four cycles of relaxation and straining. The total image acquisition time was 2.5 minutes, and the room time was 10 minutes per study. The charge for each study was \$540, including interpretation.

The levator hiatus width (H-line) averaged 5.2 ± 1.1 cm in the nonprolapse group versus 7.5 ± 1.5 cm in the prolapse group ($P < 0.001$). The levator muscular descent (M-line) averaged 1.9 ± 1.2 cm in the nonprolapse group versus 4.1 ± 1.5 cm in the prolapse group ($P < 0.001$). A cystocele was defined as descent of the bladder base below the pubosacral line. A urethrocele was defined as rotational descent of the proximal urethra during straining that increased the urethral angle to greater than 30° from the vertical. A bulge of more than 3 cm between the extended line of the anterior border of the anal canal and the tip of the rectal descensus constituted a rectocele.^{3,4} An enterocele was defined as abnormal deepening of the cul-de-sac or widening of the rectovaginal space with peritoneal contents. Data regarding organ prolapse and pelvic floor relaxation are summarized in Table I.

Pelvic pathologic features (suspected and incidental) were also demonstrated by MRI. These findings included uterine fibroids in 43 patients (26%), ovarian cyst in 34 (21%), hydroureter in 12 (7%), bladder diverticulum in 8 (5%), urethral diverticulum in 11 (7%), Bartholin gland cyst in 16 (10%), and foreign body in 11 patients (7%).

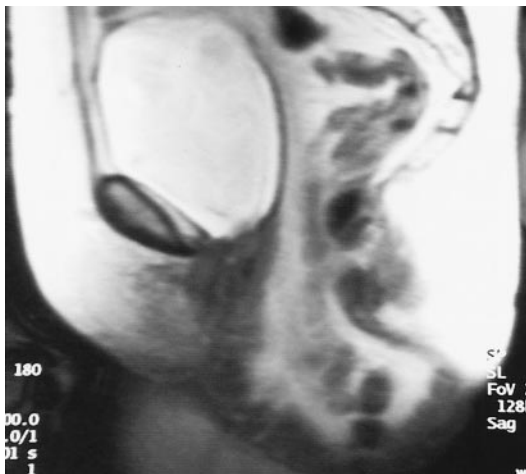


FIGURE 2. Patient with a large enterocele. It may be difficult to discern which organ or organs are responsible for a large vaginal bulge based on physical examination alone. MRI clearly demonstrates that this mass is a large enterocele.

COMMENT

A thorough evaluation of the pelvis is crucial for any woman presenting with stress incontinence and/or symptoms of pelvic prolapse. The physical examination is often insufficient for defining the nature and degree of visceral prolapse and pelvic floor relaxation. Because defects in the female pelvic floor are often multiple, attention to anterior prolapse (cystourethrocele) without attention to the pelvic floor may predispose to an increased occurrence of postoperative enterocele, uterine prolapse, and rectocele. Furthermore, restoration of the normal pelvic floor anatomy facilitates pressure transmission to the proximal urethra, thereby improving results of anti-incontinence surgery.⁵

The urologist should therefore aim to accurately diagnose visceral prolapse and pelvic floor relaxation. In the setting of a large introital bulge, it may be difficult to differentiate among cystocele, enterocele, and high rectocele by physical examination alone (Fig. 2), as prolapsing organs may “compete” for vaginal space. Therefore, pelvic imaging can provide an important extension of the physical examination. Various modalities have been used for imaging the female pelvis. Cystography (static) and fluoroscopy (real-time) are useful for viewing the bladder and its relationship to the bony pelvis, but these studies require catheterization and expose the examiner and patient to ionizing radiation. Although evacuation proctography and positive contrast peritoneography are able to demonstrate rectocele, peritoneocele, and enterocele,^{6,7} these techniques are invasive and also rely on ionizing radiation. Sonography obviates the need for ionizing radiation; however, suboptimal visualization of soft-tissue planes has limited the

use of dynamic ultrasound⁸ in the evaluation of pelvic floor relaxation. None of these diagnostic techniques can noninvasively visualize the entire pelvis nor can they directly image the support structures of the pelvic viscera.

MRI, on the other hand, can noninvasively survey the entire pelvis. The excellent differentiation between soft tissue and fluid-filled viscera provides visualization of the musculofascial support structures of the pelvic organs. Our group and others have previously demonstrated the clinical utility of MRI for evaluating bladder neck and urethral anatomy¹ and the utility of dynamic MRI for assessing pelvic floor descent and genital prolapse.^{2,3,9-11} The development of dynamic rapid sequencing has greatly improved the diagnostic utility of MRI by allowing exquisite anatomic detail during brief breath-holds. Linemann *et al.*¹¹ recently demonstrated cine images on CD-ROM showing that dynamic magnetic resonance colpocystorectography is useful in the assessment of pelvic floor relaxation. Various instilled liquids were used to opacify the urethra, bladder, vagina, and rectum.

In fact, instrumentation is not necessary for opacification of the pelvic viscera. Our dynamic MRI protocol does not require any patient preparation or instrumentation. The urethra, bladder, uterus, vagina, rectum, bowel, ovaries, and ureters (if abnormally dilated) are visible on MRI without instilled agents. In a study correlating physical examination and MRI with operative findings, dynamic MRI was more accurate than physical examination in demonstrating cystocele, enterocele, uterine hypermobility, and vaginal vault prolapse. Furthermore, with significant prolapse, documentation of ureteral dilation is important as a baseline study, so that resolution or persistence on follow-up imaging may be put into proper context. Dynamic MRI clearly demonstrates the ovaries, revealing any cysts or other abnormalities that may affect the decision to perform oophorectomy at the time of hysterectomy.

The HMO system is straightforward and differentiates between organ prolapse and pelvic floor descent. The H-line spans the distance from the pubis to the posterior anal canal and measures the width of the levator hiatus. The M-line measures muscular pelvic floor relaxation (ie, the descent of the levator plate from the pubococcygeal line) (Fig. 1). Trauma to the pubococcygeus and ileococcygeus, usually from childbirth, results in widening of the hiatus and laxity of the musculofascial supporting structures.⁵ The result is a sloping levator plate, with the more vertically oriented vagina and rectum tending to slide down through the widened hiatus. Thus, the H and M lines both tend to increase with significant pelvic floor relaxation, representing levator hiatal widening and levator plate descent, respectively. The O classification stages the visceral prolapse. Whether cystocele, urethrocele, rectocele, enterocele, or

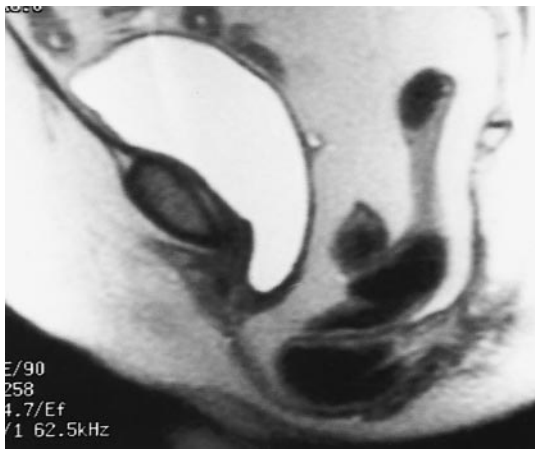


FIGURE 3. Severe pelvic floor relaxation with a mild cystourethrocele, severe enterocele, and severe rectocele. HMO classification: H (9.8 cm) M (6.3 cm) O (U2C2E4R4).

uterine descensus, prolapse is defined as the degree of visceral descent beyond the H-line.

A case of severe pelvic floor relaxation with a mild cystocele, severe enterocele, and severe rectocele (Fig. 3) would be classified as H (9.8 cm) M (6.3 cm) O (U2C2E4R4). Prolapse, however, does not necessarily correlate with pelvic floor relaxation. For example, Figure 2 depicts a case of mild pelvic floor relaxation and a large enterocele after hysterectomy.

Dynamic MRI is noninvasive, relatively inexpensive (\$540, including interpretation), requires no patient preparation and minimal cooperation, and does not expose the examiner or patient to ionizing radiation. There are, however, several limitations with this technique. Defining normal values for the H and M lines is difficult, as it would be quite expensive to perform dynamic MRI scans on nulliparous women without any urologic complaints. The patients in the nonprolapse group included those for whom we desired an imaging study to evaluate pathologic features other than pelvic prolapse, such as recurrent infection, pelvic pain, and urethral pain. Another limitation is that a collapsed rectocele may not be visualized because of competition among prolapsing pelvic organs for limited introital space. In fact, physical examination has been shown to be slightly more accurate in demonstrating rectocele formation than MRI.

Additionally, the study must be performed supine, simply because no upright MRI machines are currently available. However, dynamic MRI with relaxing and straining views has been shown to clearly demonstrate organ prolapse during straining in the supine position.^{3,11} An erect MRI is the next logical advance. Finally, claustrophobic patients and those with cardiac pacemakers cannot enter the enclosed magnet. Despite these limitations, dynamic MRI has become the study of choice at our institution for evaluating high-grade pelvic prolapse and pelvic floor relaxation. As this is a

new technique, a standardized system for describing and quantifying organ prolapse and pelvic floor relaxation is important.

CONCLUSIONS

The HMO classification affords a straightforward method of describing, staging, and quantifying pelvic floor relaxation and pelvic visceral prolapse. Dynamic MRI provides an inexpensive, noninvasive, and comprehensive visualization of the female pelvis. MRI is a useful extension of the physical examination and is more accurate than physical examination alone in diagnosing pelvic prolapse and pelvic floor relaxation. MRI allows the urologist to rule out significant ureteral obstruction that may be associated with severe prolapse and also detects other pathologic processes that may be germane to the urinary tract. Dynamic MRI obviates the need for cystourethrography, pelvic ultrasound, or intravenous urography in the assessment of pelvic prolapse and pelvic floor relaxation and has thus become the study of choice at our institution for evaluating the female pelvis.

REFERENCES

1. Klutke C, Golomb J, Barbaric Z, *et al*: The anatomy of stress incontinence: magnetic resonance imaging of the female bladder neck and urethra. *J Urol* 143: 563–566, 1990.
2. Gousse AE, Barbaric ZL, Safir MH, *et al*: Dynamic “HASTE” MRI sequence in the evaluation of all female pelvic pathology. *J Urol* 159: 328, 1998.
3. Lienemann A, Anthuber CJ, Baron A, *et al*: Dynamic MR colpocystorectography. A new method for evaluating pelvic floor descent and genital prolapse. *Aktuell Radiol* 6: 182–186, 1996.
4. Yoshioka K, Matsui Y, Yamada O, *et al*: Physiologic and anatomic assessment of patients with rectocele. *Dis Colon Rectum* 34: 704–708, 1991.
5. Babiarz JW, and Raz S: Pelvic floor relaxation, in Raz S (Ed): *Female Urology*, 2nd ed. Philadelphia, WB Saunders, 1996, pp 445–456.
6. Halligan S, and Bartram CI: Evacuation proctography combined with positive contrast peritoneography to demonstrate pelvic floor hernias. *Abdom Imaging* 5: 442–445, 1995.
7. Bremmer S: Peritoneocele. A radiological study with defaeco-peritoneography. *Acta Radiol Suppl* 413: 1–33, 1998.
8. Mouritsen L: Techniques for imaging bladder support. *Acta Obstet Gynecol Scand Suppl* 166: 48–49, 1997.
9. Yang A, Mostwin JL, Rosenshein NB, *et al*: Pelvic floor descent in women: dynamic evaluation with fast MR imaging and cinematic display. *Radiology* 179: 25–33, 1991.
10. Goodrich MA, Webb MJ, King BF, *et al*: Magnetic resonance imaging of pelvic floor relaxation: dynamic analysis and evaluation of patients before and after surgical repair. *Obstet Gynecol* 82: 883–891, 1993.
11. Lienemann A, Anthuber CJ, Baron A, *et al*: Dynamic MR colpocystorectography assessing pelvic-floor descent. *Eur Radiol* 7: 1309–1317, 1997.